



# **Management of the facial nerve**

## **Facial reanimation after facial palsy**

**Philippe Pasche**

Service d'ORL et de chirurgie cervico-faciale

CHUV- Lausanne

# Management of the facial nerve during parotidectomy: principles

- Pre-operative normal fonction
  - Preservation of the facial nerve if possible
  - Microdissection of the nerve
  - Sacrifice of the FN has no impact on DFS
  - Positive margin on FN has no negative impact on the recovery fonction after grafting
  - Pronostic factor of neural invasion
    - Medial lobe tumors
    - Histologic type ( adenoid cystic carcinoma)

Does a positive neural margin affect outcome in facial nerve grafting M.Wax et all Head & Neck june 2007

Facial nerve fonction in carcinoma of the parotid gland C Terhaard europ j of cancer 42 2006

Management of salivary gland tumors United Kingdom guidelines S sood The journal of laryngology & otology 130 suppl S2 2016

## Goals of the reanimation

- Symetry at rest
- Symetry of the smile
- Synchronous contraction
- Spontaneous mouvements
- No synkinesis
- Natural expression

# TAKE IN CONSIDERATION

- Life expectation of the patient
- Prognostic of the initial pathology
- Other cranial nerve impairment
- Experience of the surgeon
- Expectancy of the patient
- Synchronous reanimation with the tumor ablation
- Reproducible outcomes

# Surgical procedures

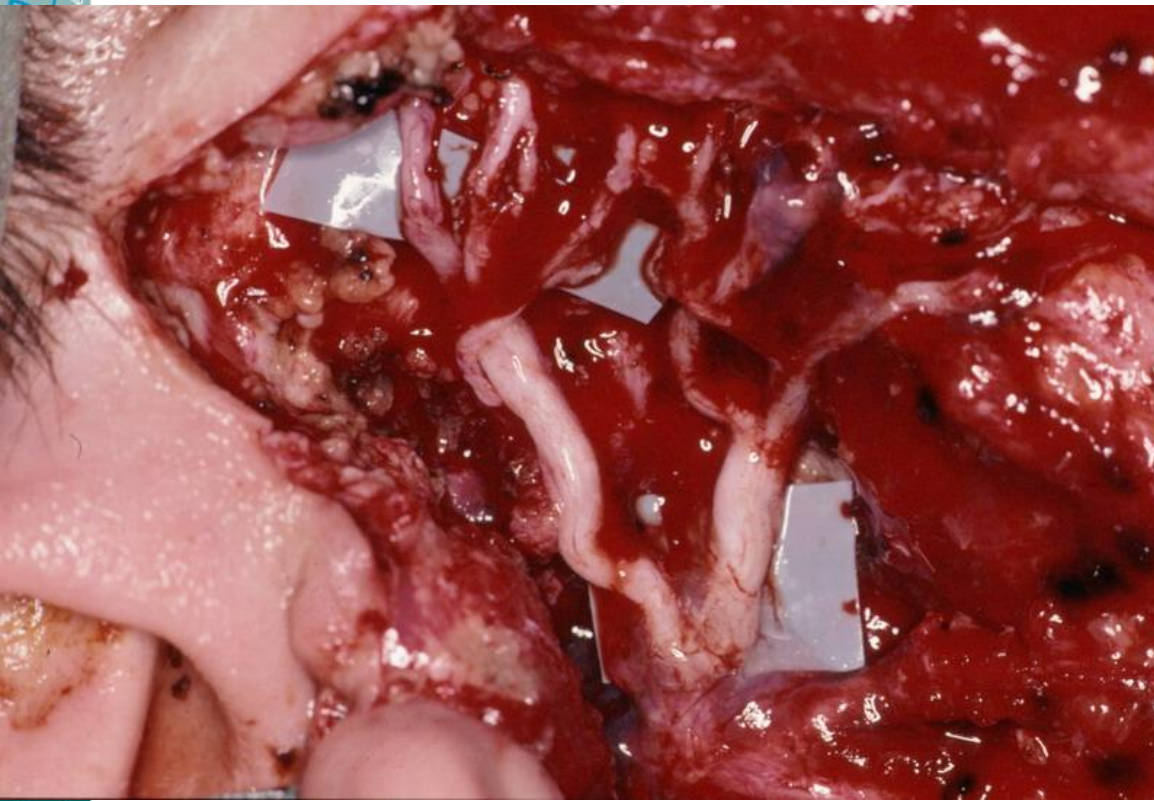
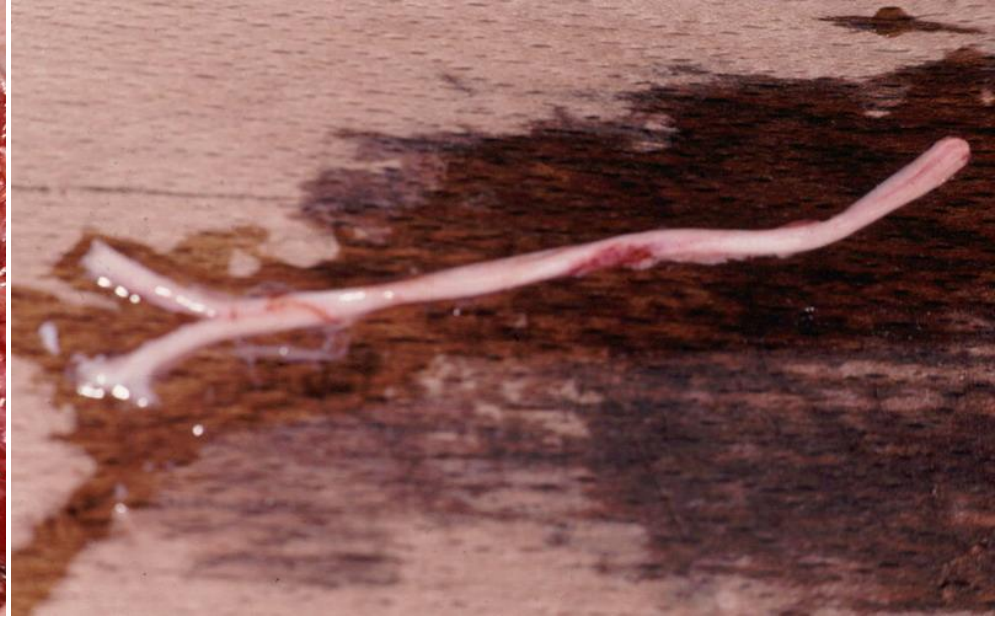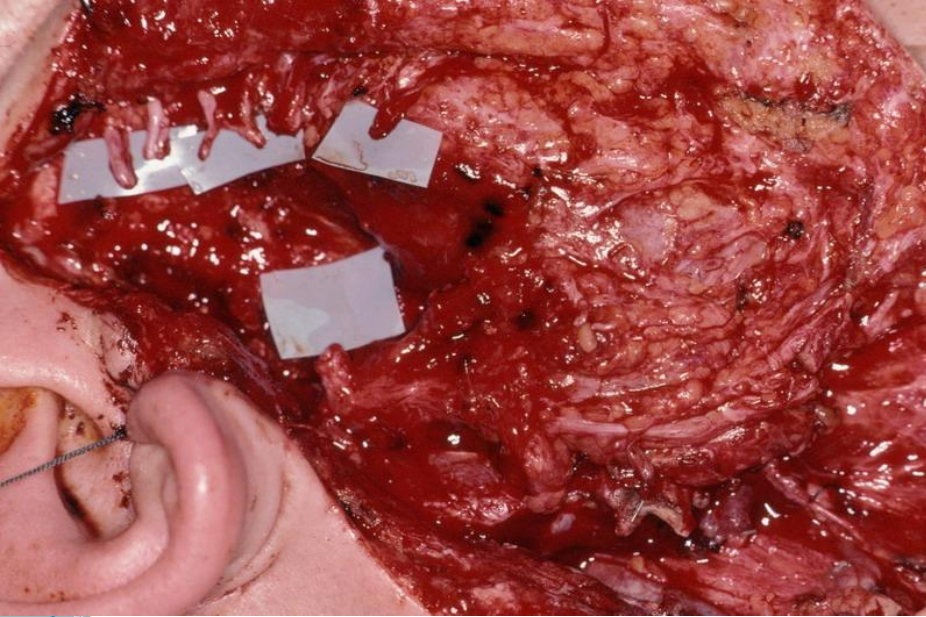- Direct nerve repair
- Interposition graft
- Nerves transfert
  - Masseteric –facial
  - Hypoglosso-facial
  - Crossfacial nerve grafting
- Muscle transfert
  - Temporal myoplasty
  - Free muscle transfert
- Static suspension

# FACIAL PARALYSIS

- Acute : < 3-4 weeks
- Intermediate: 4 weeks to 2 years
- Late : > 2 years

Stimulation up to 72h after the nerve section





Epineural suture

Microscope

Nylon 11-0

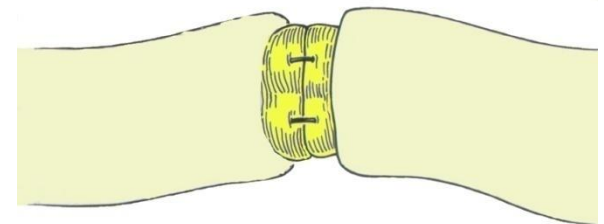
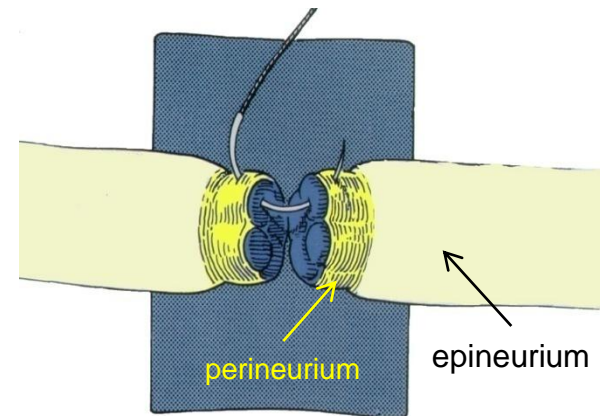
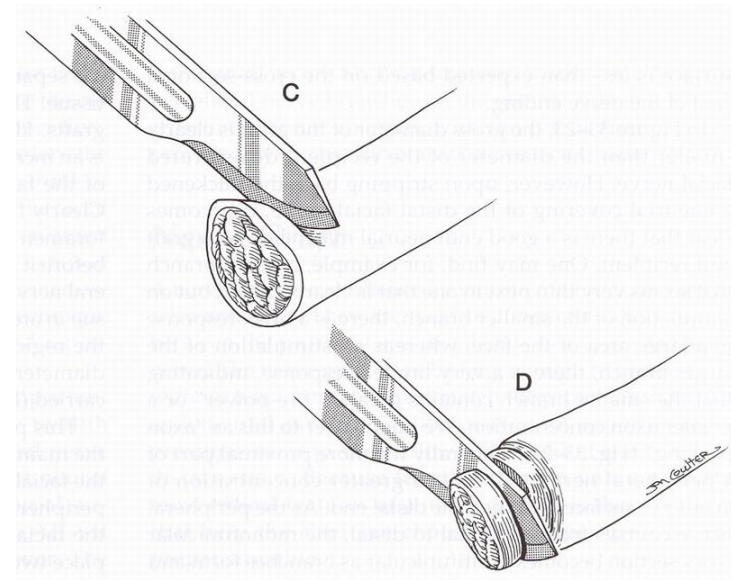
# DIRECT REPAIR

- Reconnection of the nucleus to the motor endplate
- Anatomical and physiological advantages
- Best method if possible
- Timing: < 30 Days
- synkinesis and lack of contraction

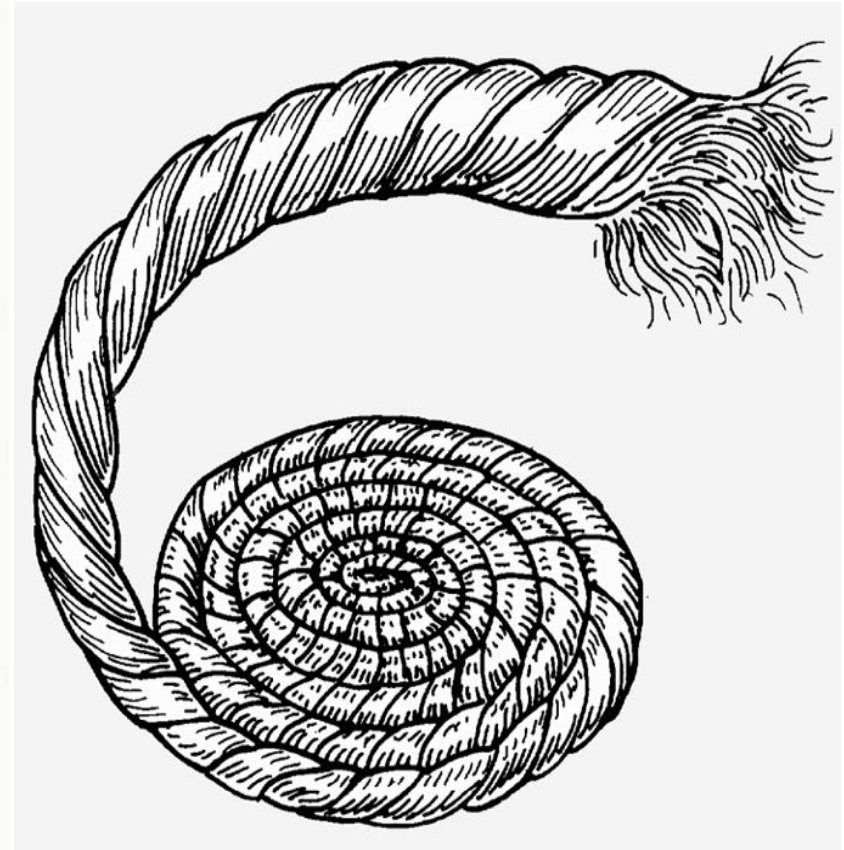
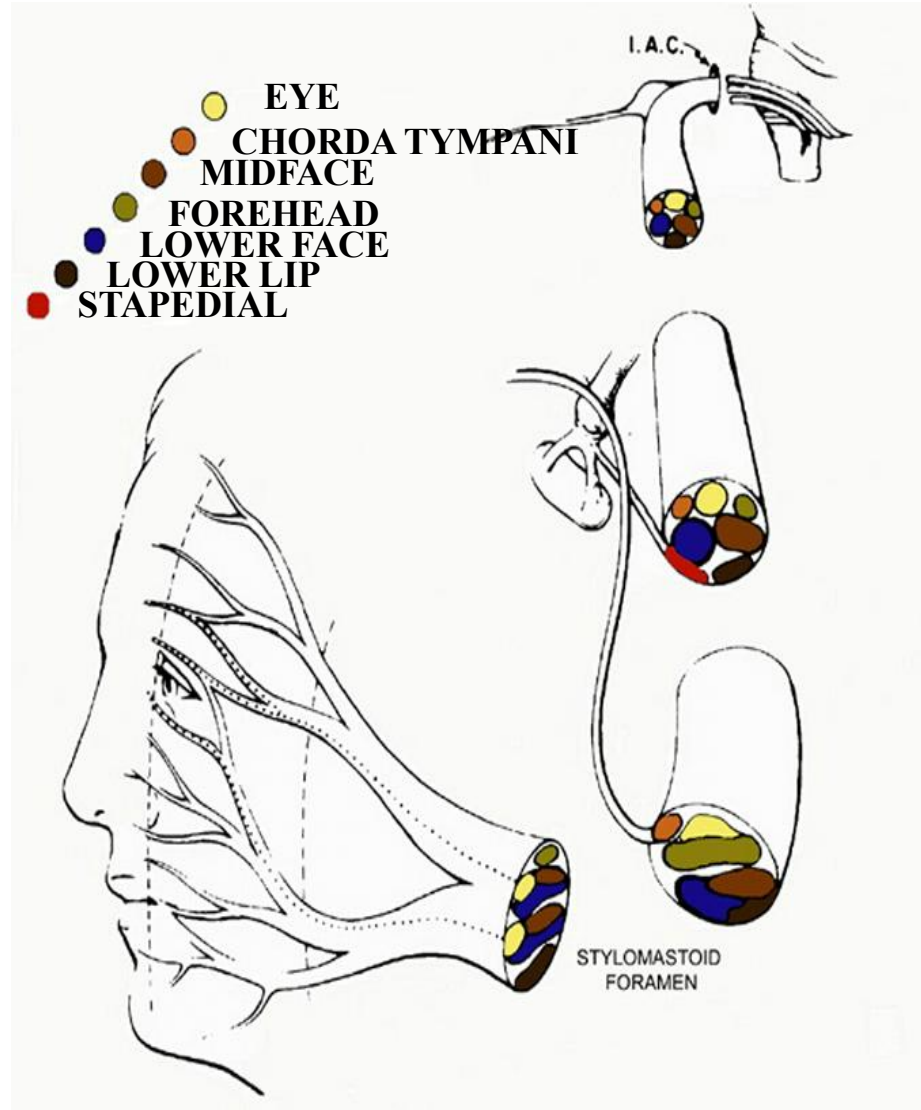


# NERVE COAPTATION

- Microscope
- Strip back the epineurium
- Perineurial sutures
- Match the endoneurial surface
- Suture nylon 9.0 – 11.0
- Without any tension
- Tubulisation with a vein
- Fibrine glue
- interpositional Nerve graft



# SPACIAL ORIENTATION OF THE FACIAL NERVE

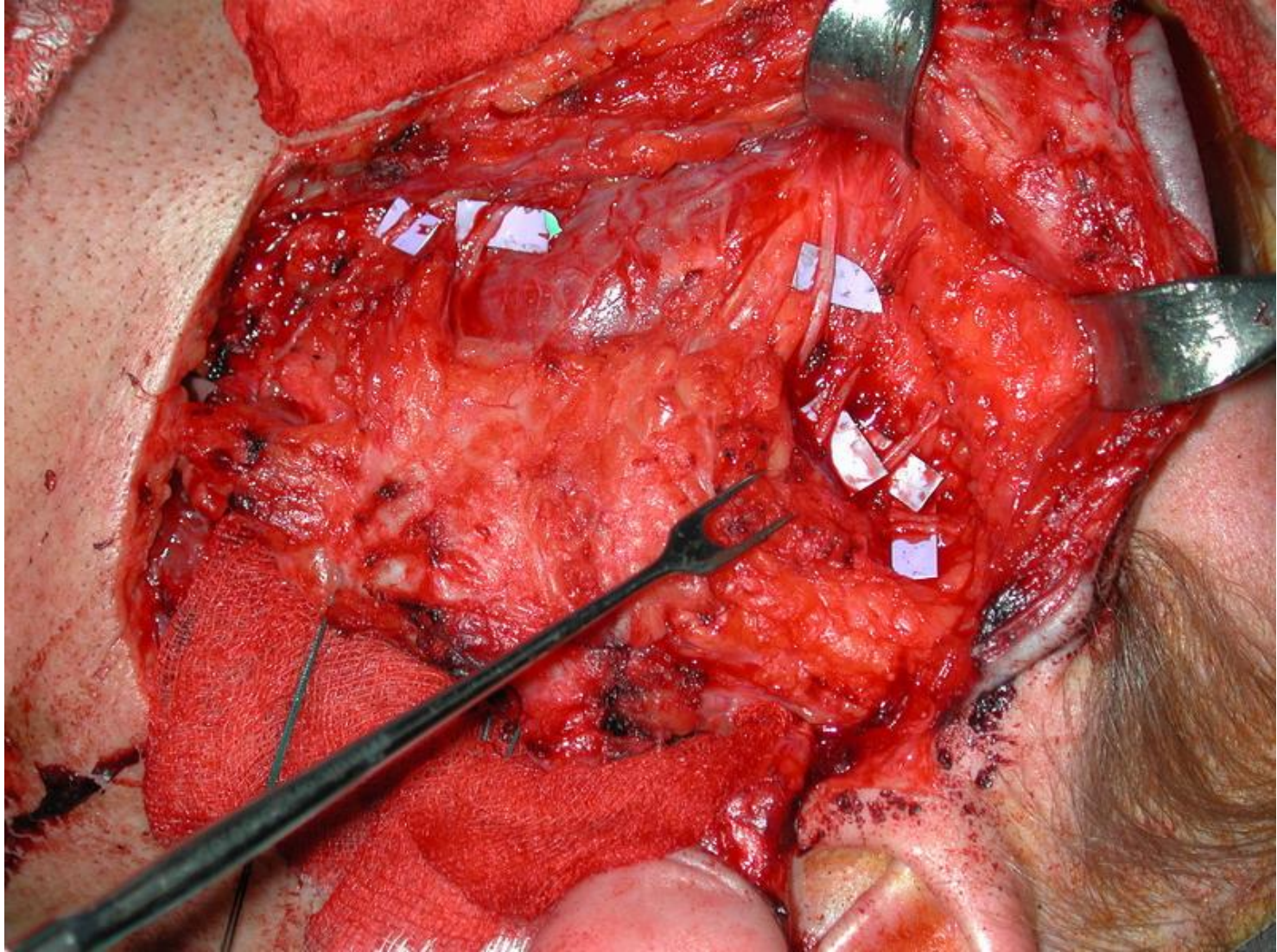


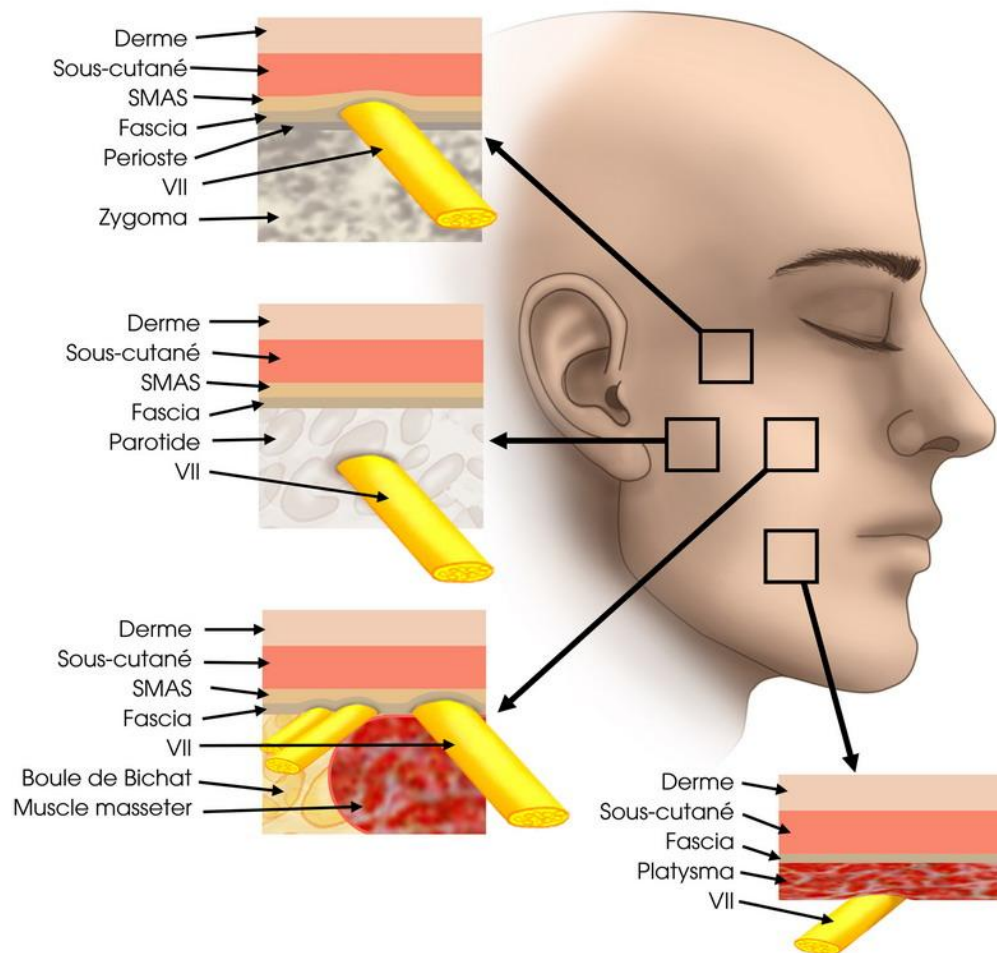
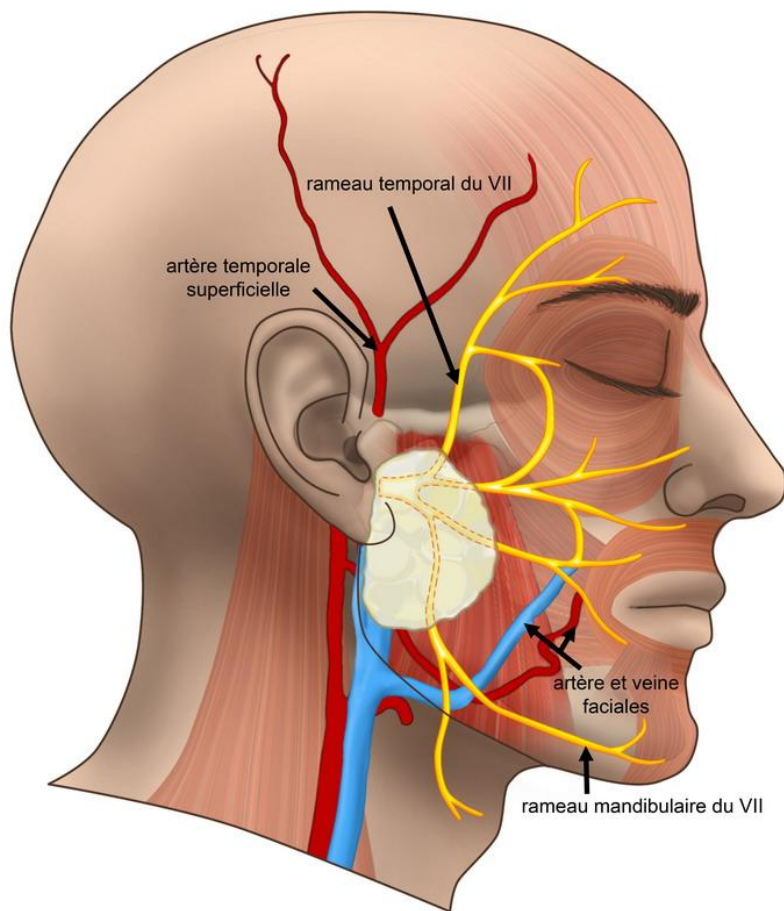
# Choice of the graft

nerve	Length	Site	deficit
Great Auricular	7-10 cm	neck	Ear lobe
<i>Sural</i>	40 cm	leg lat.	foot lat.
<i>lat ante-brachial</i>	8-10 cm	Forearm	forearm
<i>Thoraco Dorsal</i>	10-15cm	dorsal	Latisimus dorsi



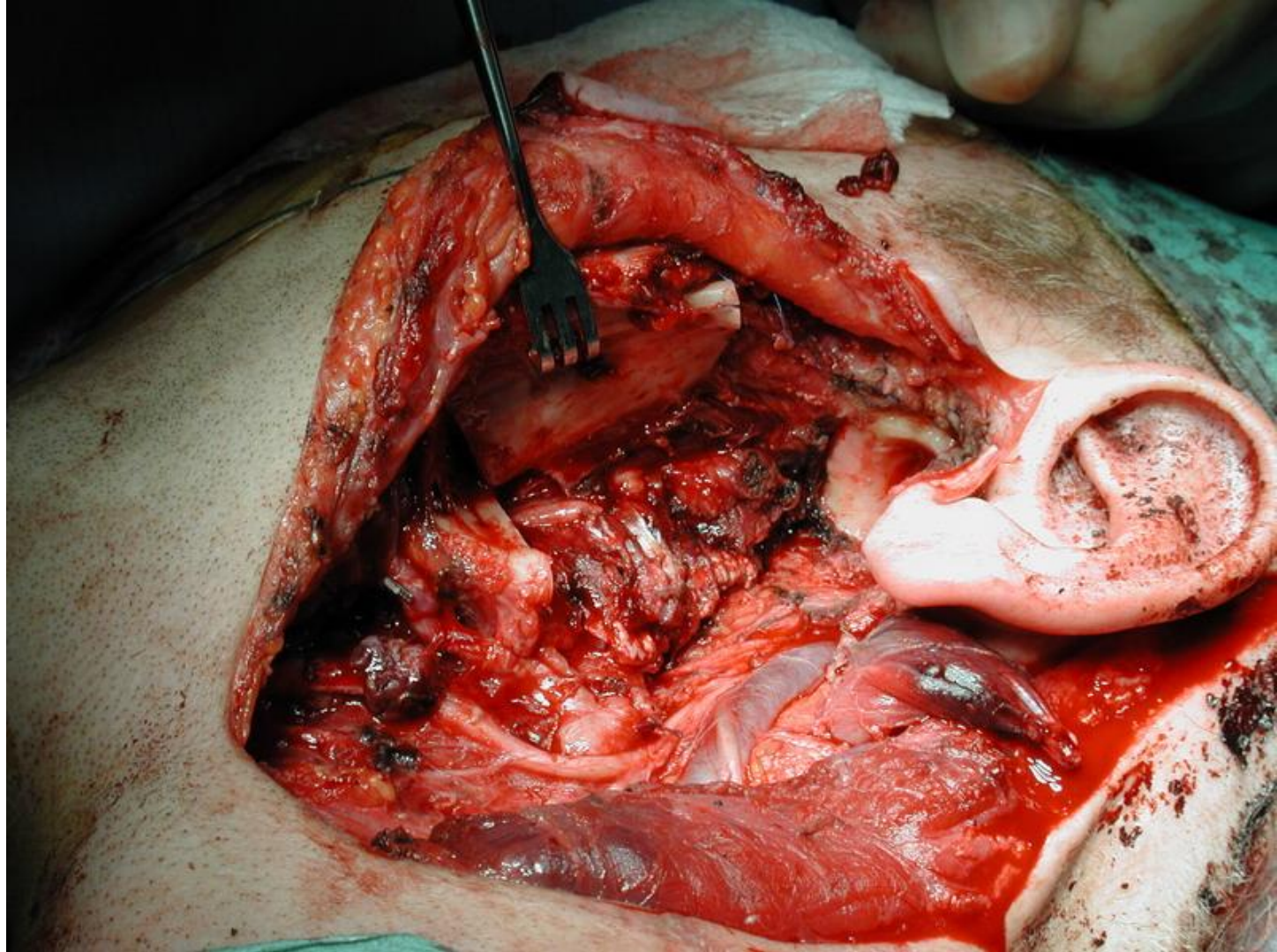
# ADENOID CYSTIC CARCINOMA OF THE PAROTID







# ADENOID CYSTIC CARCINOMA OF THE PAROTID GLAND





# The reconstruction after parotid surgery

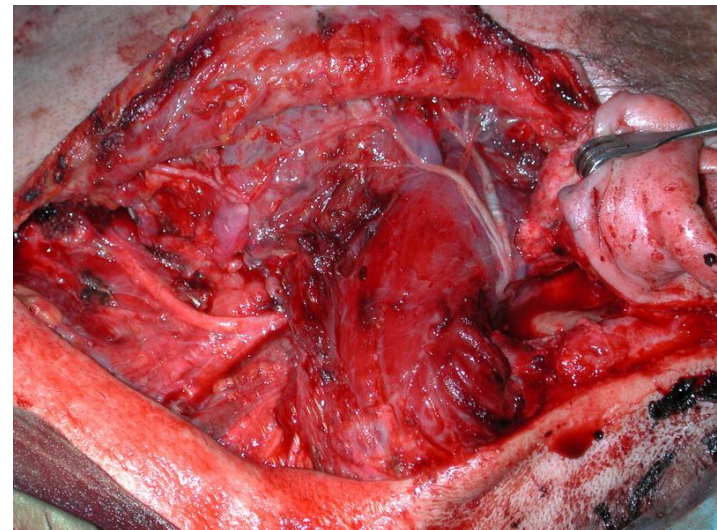
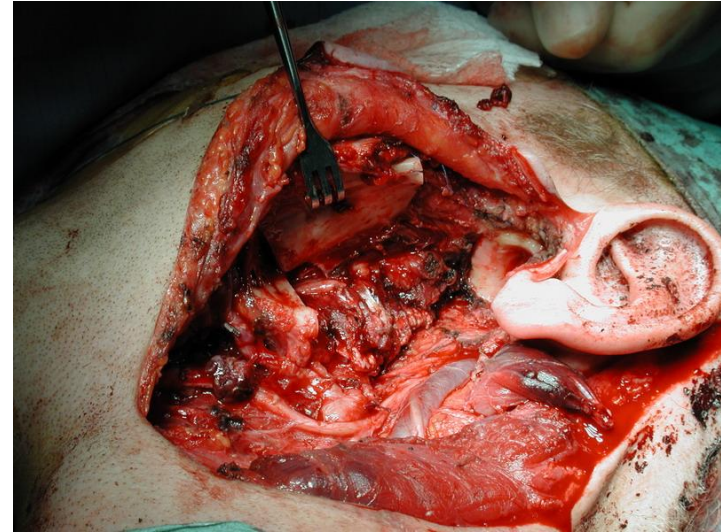
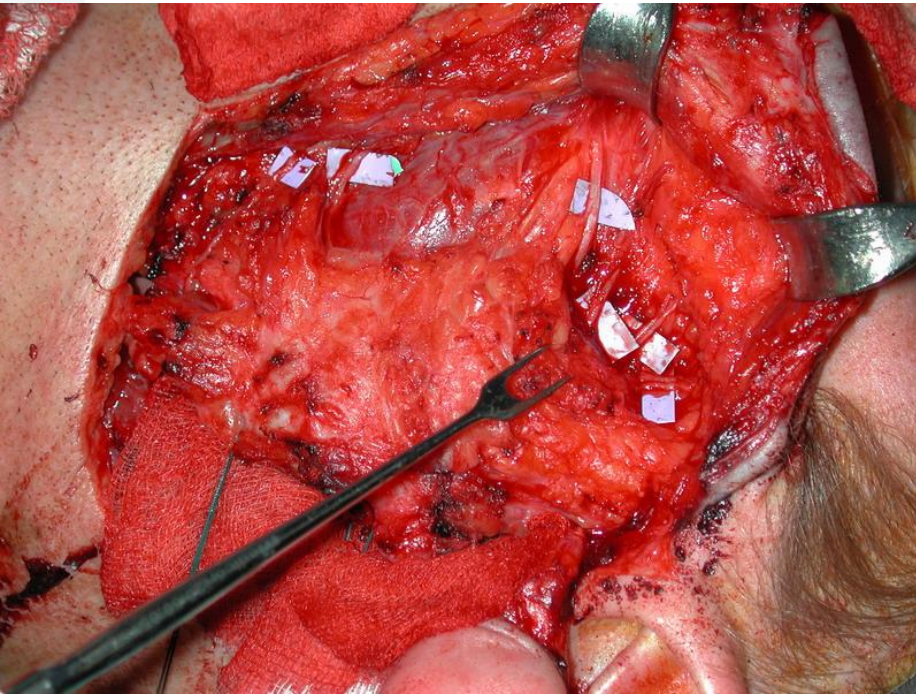
- 3 D reconstruction
  - skin
  - parotid gland / musculature
  - mandibule
  
- Fonctionnal rehabilitation
  - Interpositional nerve graft
  - Muscle transfert
  - Static suspension

# The reconstruction of the parotid area after parotid surgery : principles

- requirement
  - Skin color match
  - volume
  - Reliable vascularisation of tissue grafting ?
  - Low morbidity of the donor site
- Choice of the flap
  - Fat
  - Local and regional flaps
  - Pediculed flaps
  - Free flaps

# LOCAL MUSCLE FLAP

## Adenoid cystic carcinoma of the parotid

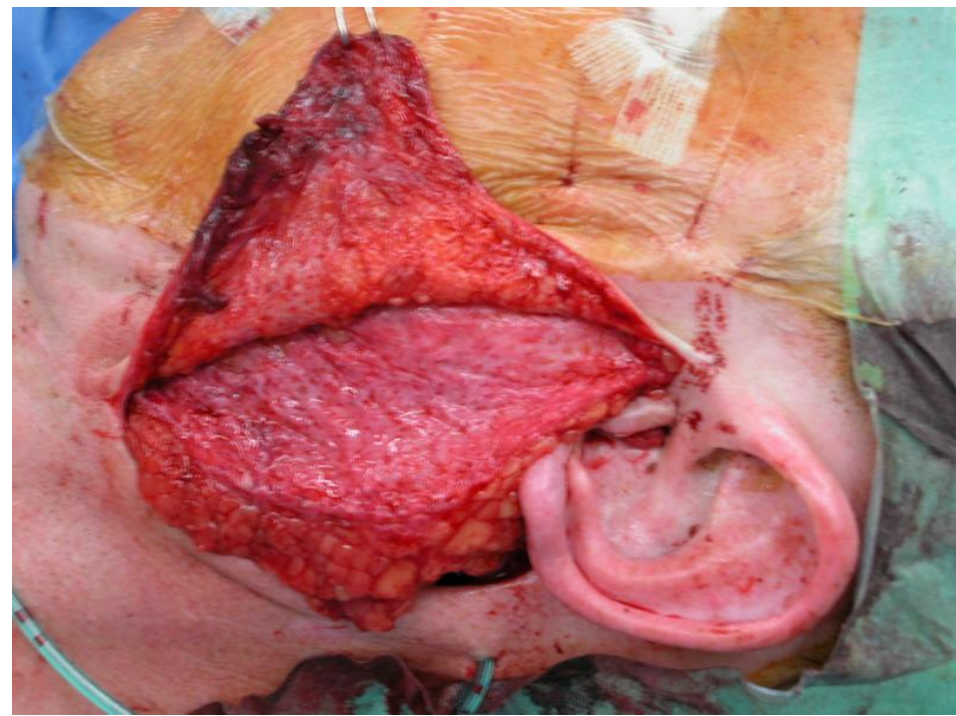
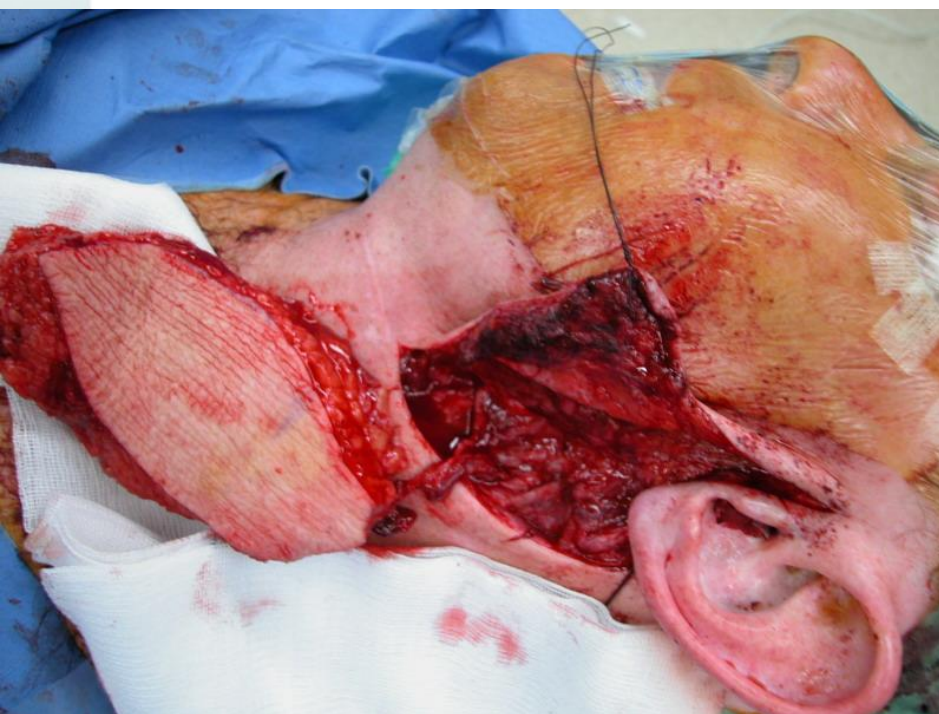

Total parotidectomy and  
mandibular osteotomy

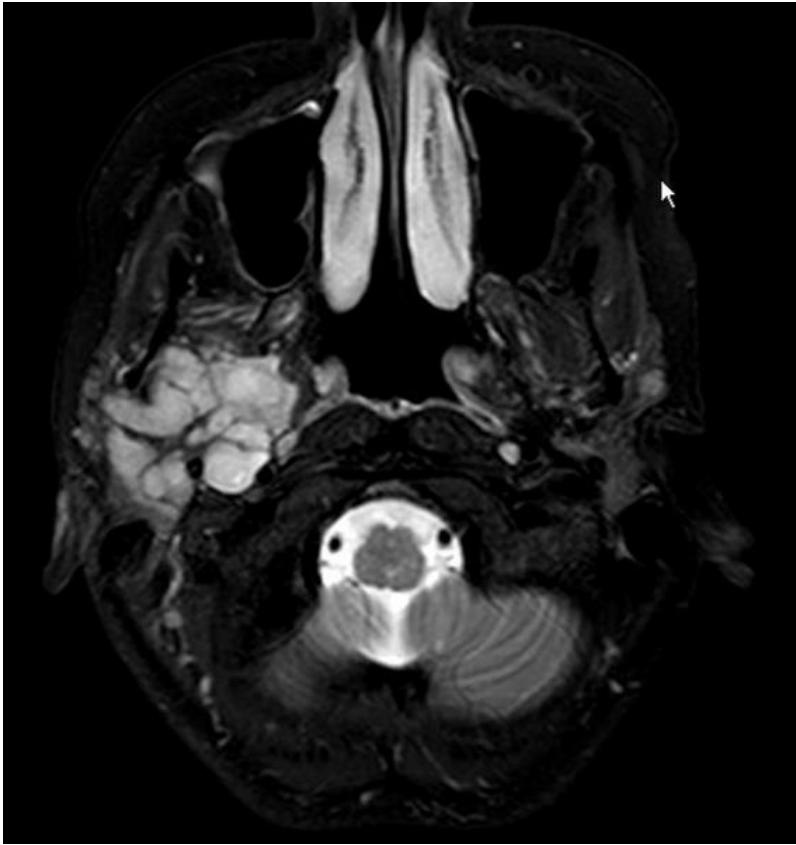Sternocleidomastoid muscle flap rotation  
and intramastoid facial nerve graft →



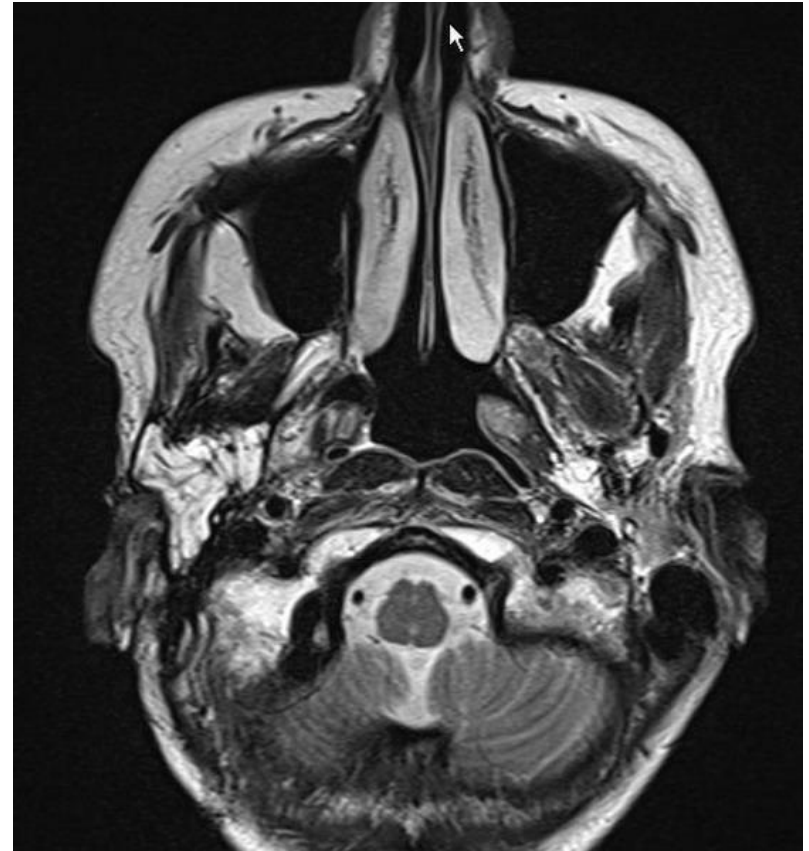# LAMBEAU LATÉRAL DE LA CUISSE



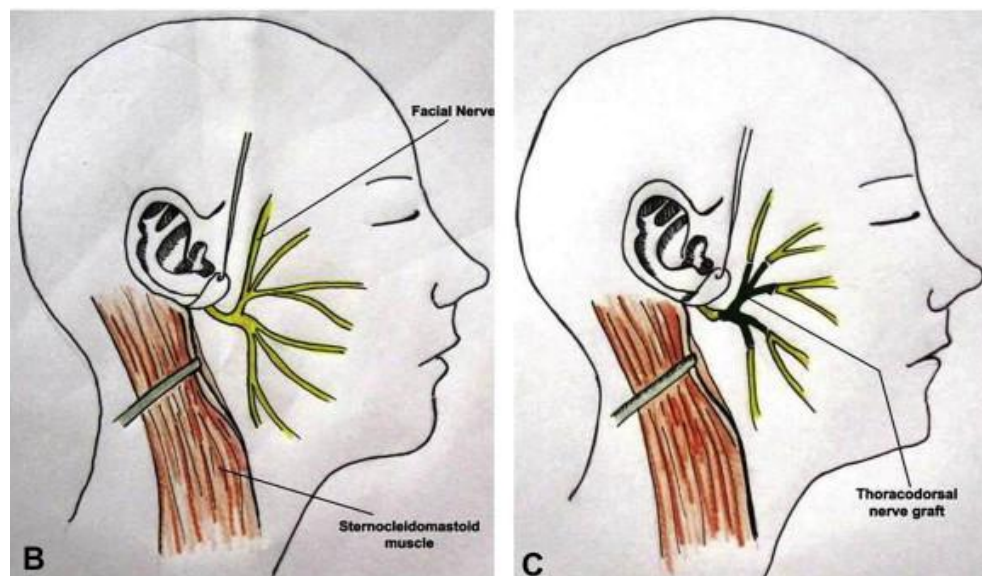
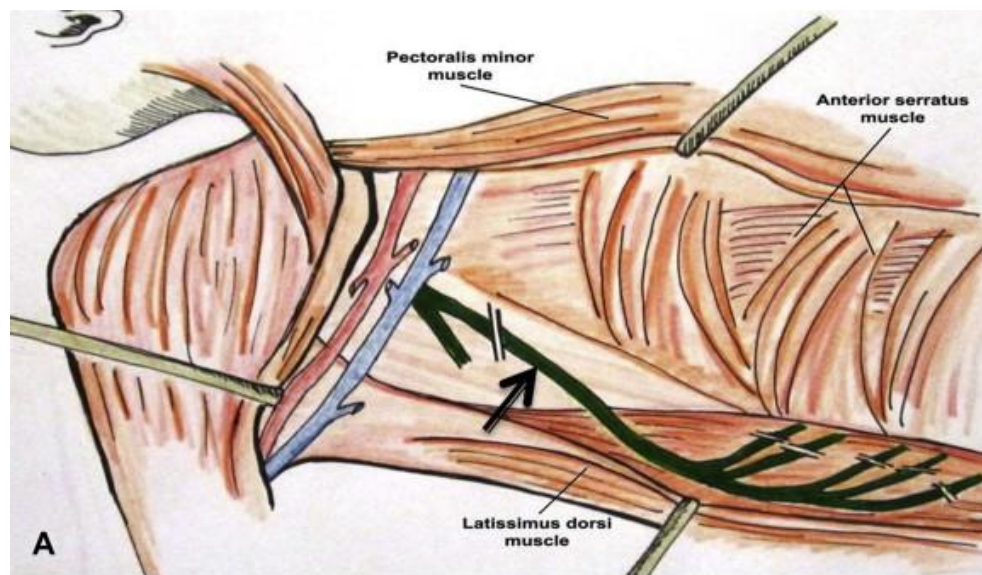
# Adenoid kystic carcinoma of the deep lobe of the parotid gland



Pre



1 year after



Thoracodorsal nerve graft for reconstruction of facial nerve branching  
F. Biglioli. Journal of Cranio-Maxillo-Facial Surgery. 2014



# Interpositional nerve grafting after radical parotidectomy

- Good symmetry at rest
- Inconsistent dynamic function
- Delay of recovery : 5-14 months
- Age related outcomes
- Synkinesis
- Radiotherapy has no deleterious effect on function

# Interpositional nerve grafting after radical parotidectomy: Results

Serie	N	HBI	II	III	IV	V	VI
Lee 2015				35%	39%	13%	13%
Biglioli 2013	7	2	2	3			

Thoracodorsal nerve graft for reconstruction of facial nerve branching, F Biglioli: J Cranio-Maxillo-Facial Surgery 42 : 2014

Functional outcomes of multiple sural nerve grafts for facial nerve defects after tumor ablative surgery: M Lee; Arch. Plast .Surg vol 42 July 2015

# How to improve the function?

- Symmetry at rest
- Consistant symmetry of smile
- Spontaneous facial expression
- No synkinesis or spasticity

Interpositional nerve graft combined with  
nerve transfert

# Nerve source characteristics

nerve	Tonus at rest	Commisural mouvement	Spontaneous expression	synkinesis
Interpositional facial graft VII	+++	+ / inconsistant	+++	+++
Masseteric nerve V	—	+++ / reproductible	Automatic mouvements	—
Hypoglossal nerve XII	+++	+ / inconsistant	Automatic mouvement	++
CFNG VII	+	+ / inconsistant	++	—

# Combined nerve grafting after radical parotidectomy : proximal facial nerve stump available

- VII-VII for mandibular and orbito-zygomatic branches
- V- buccal branches
- XII- buccal branches
- Add static suspension in every cases !

Facial nerve reconstruction with concurrent masseteric nerve transfert and cable grafting. J Owusuet al; JAMA Facial Plastic Surg sept 2016

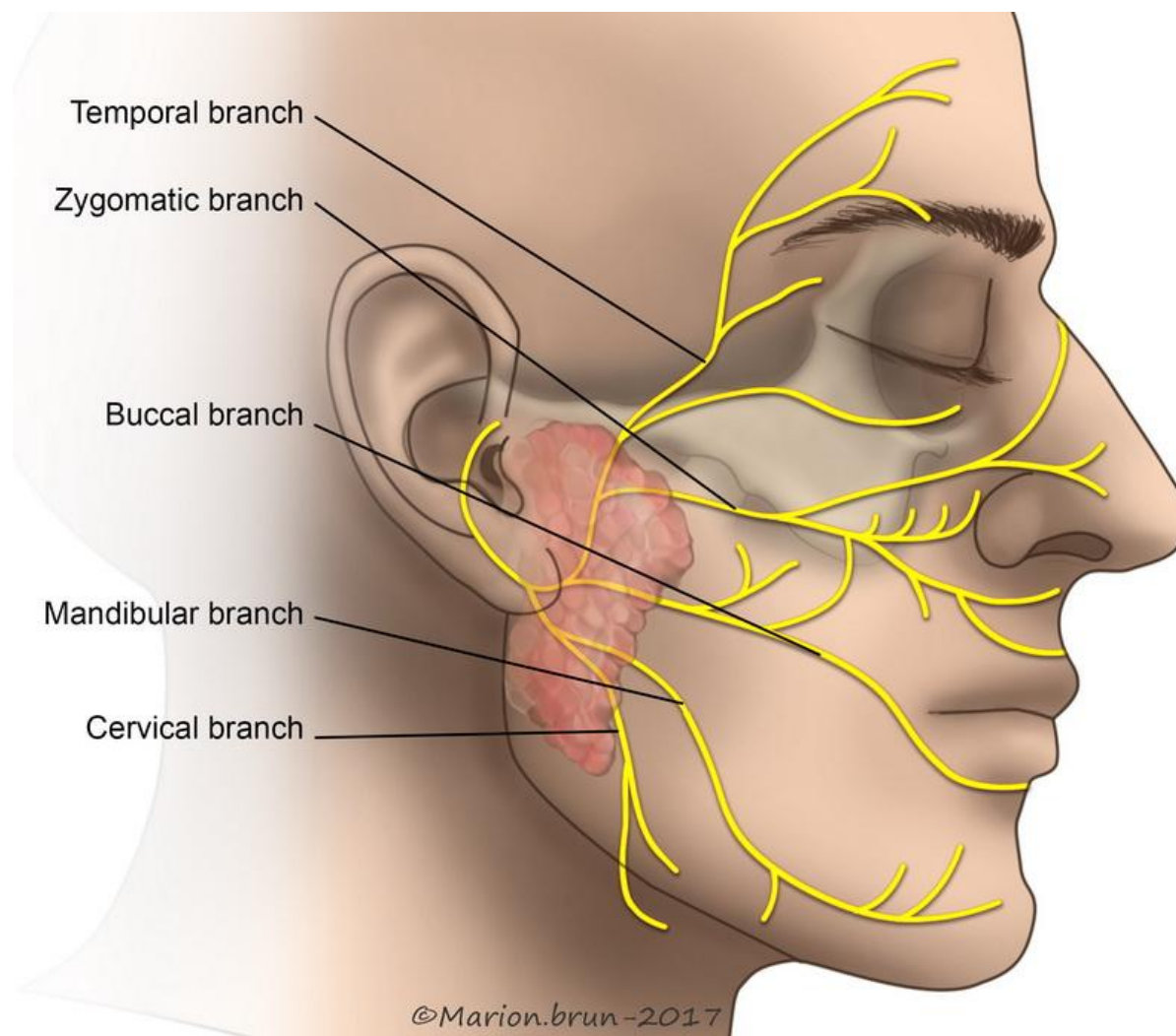
Facial nerve repair technique. P Casas-Rodera et al Acta Otorrinilaryngol Esp. 58 ( 4) 133-7 2007

Masseteric to buccal branch nerve transfer S Bayarak et al. Curr Opin Otolaryngol Head Neck Surg 25: 280 -285 2017

# Combined nerve grafting after radical parotidectomy : proximal facial nerve stump not available

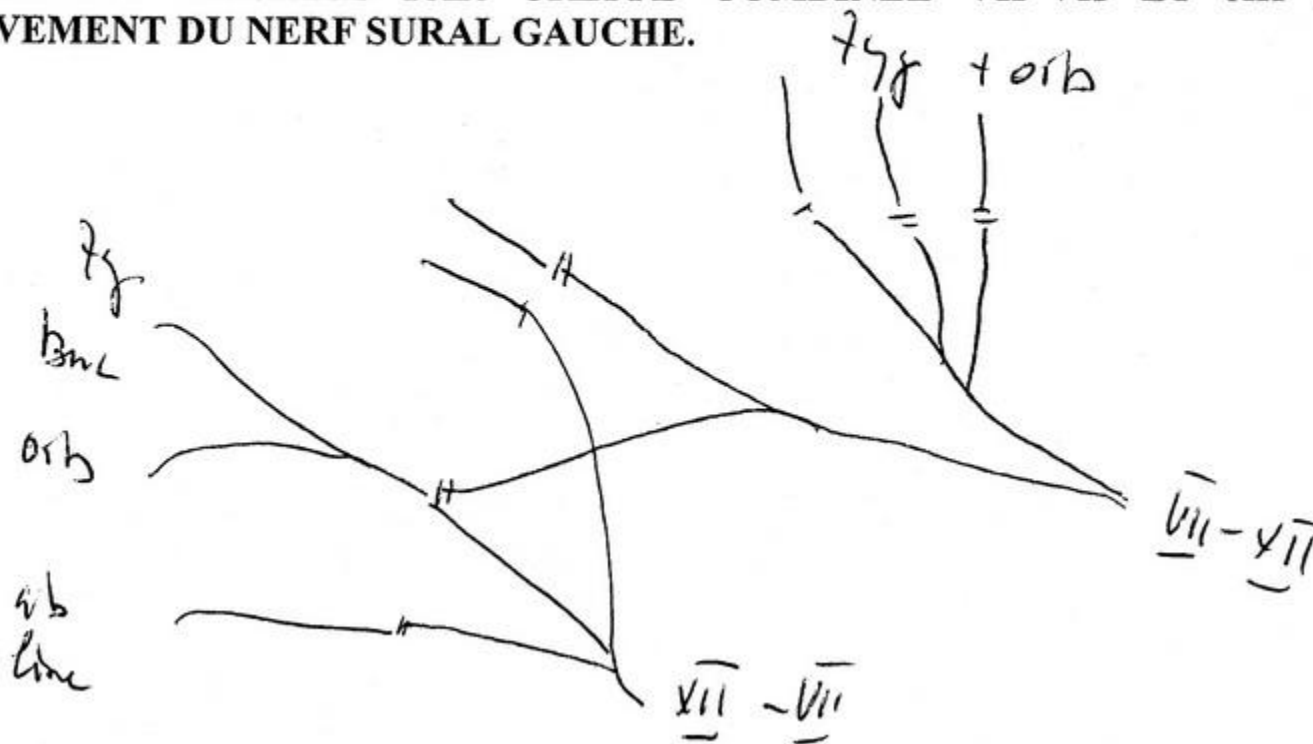
- V- VII
- XII- VII
- Add CFNG in selected cases





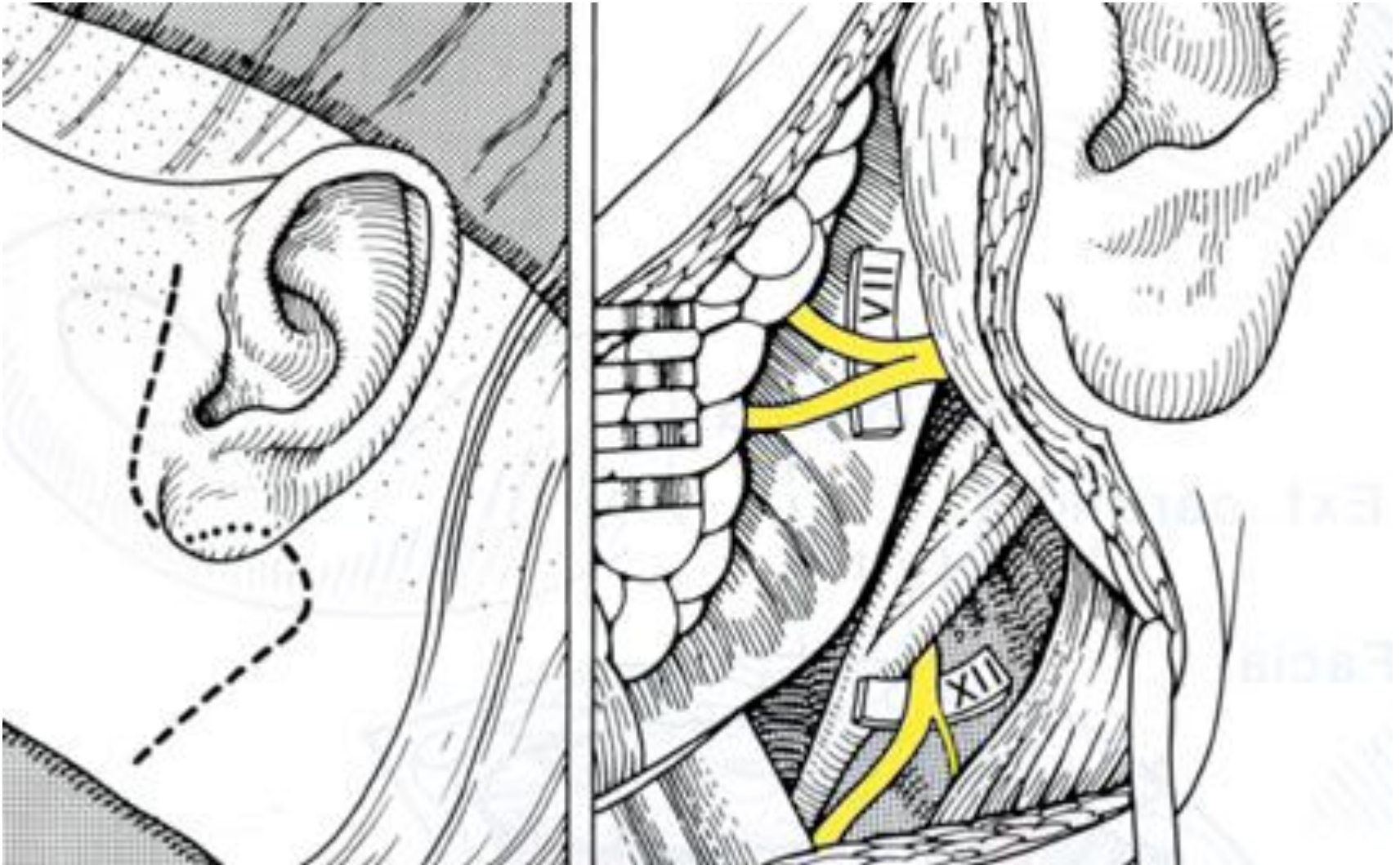
Type d'opération :

REANIMATION FACIALE PAR GREFFE COMBINEE VII-VII ET XII-VII,  
PRELEVEMENT DU NERF SURAL GAUCHE.



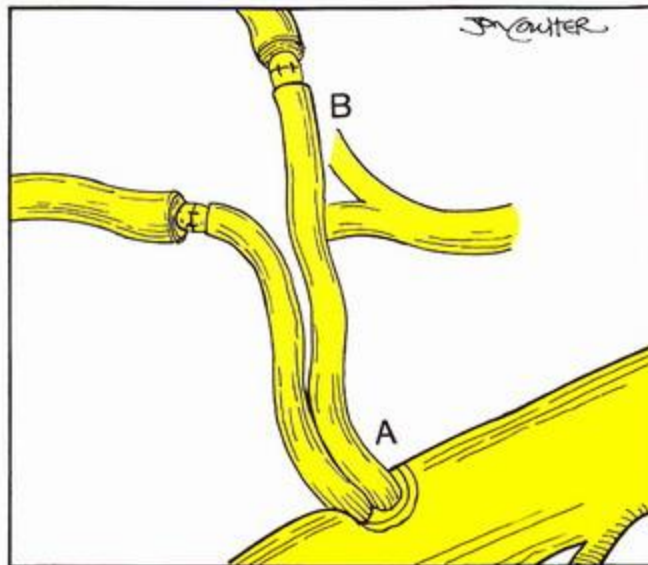
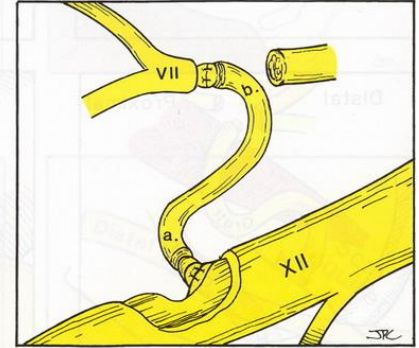
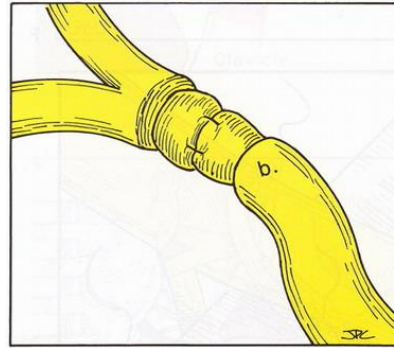

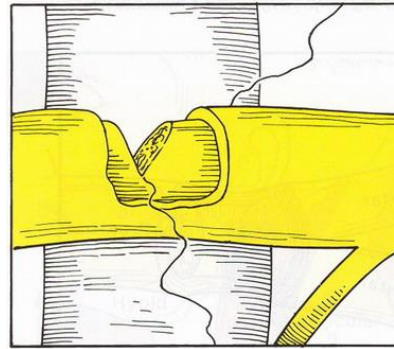
# hypoglossoglossal anastomosis

## Anatomy



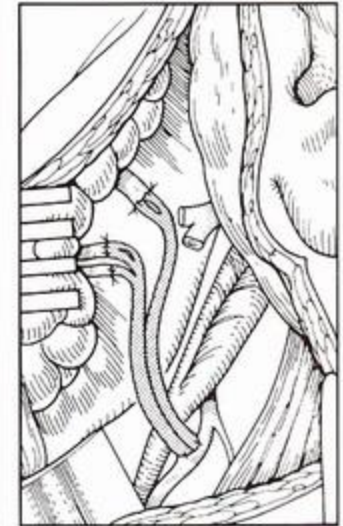
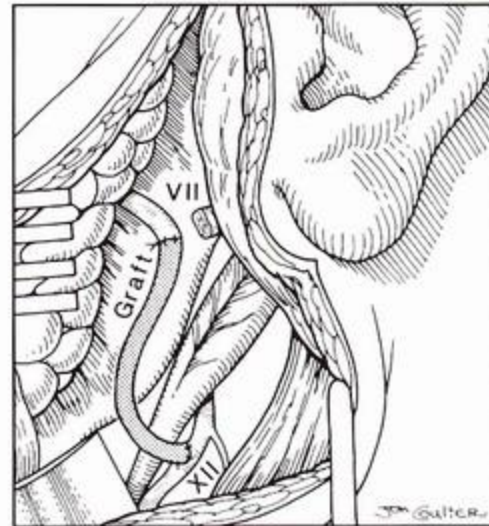


# Anastomosis VII-XII End to side « jump graft »

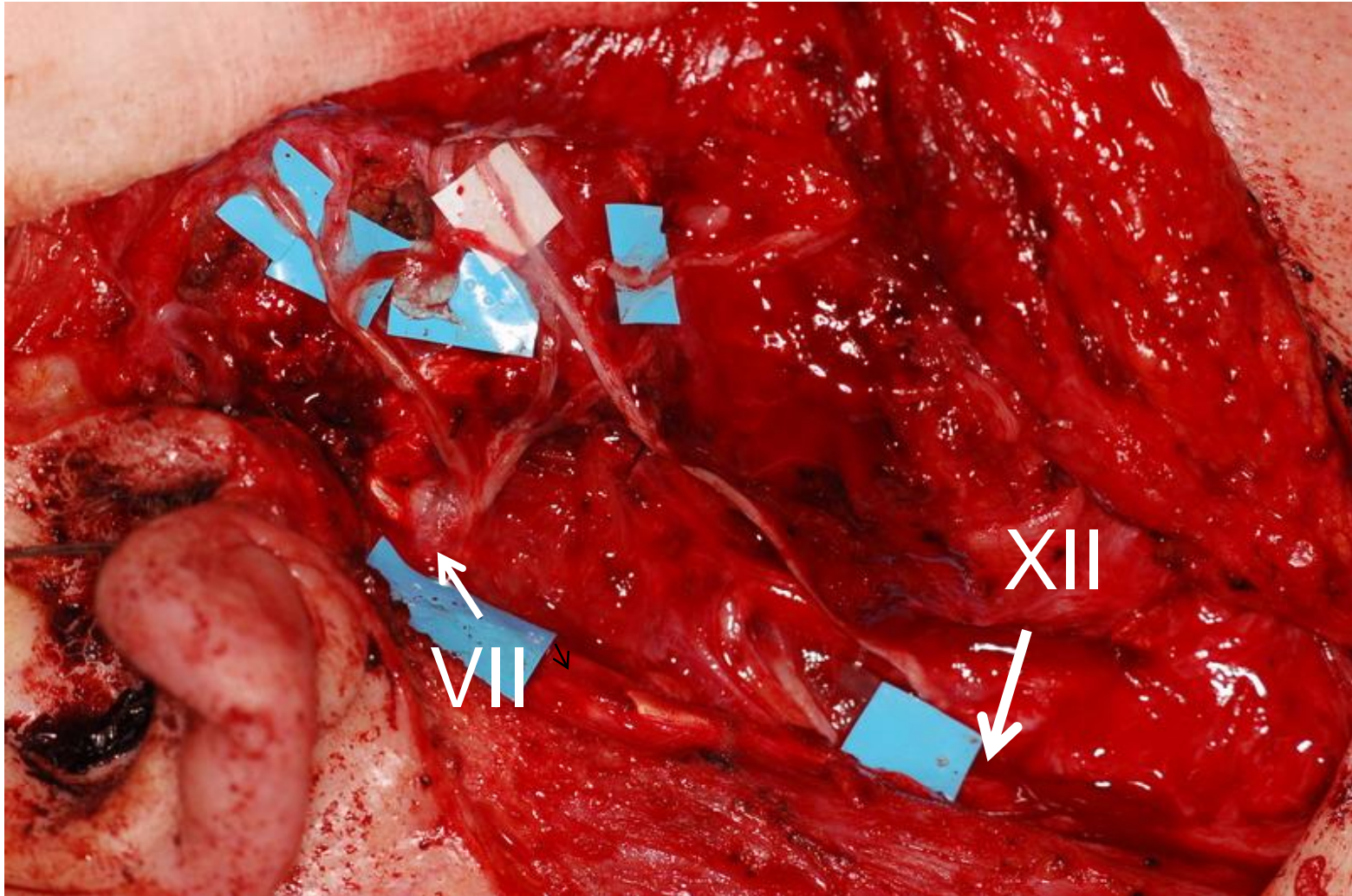


Single Cable

Double Cable

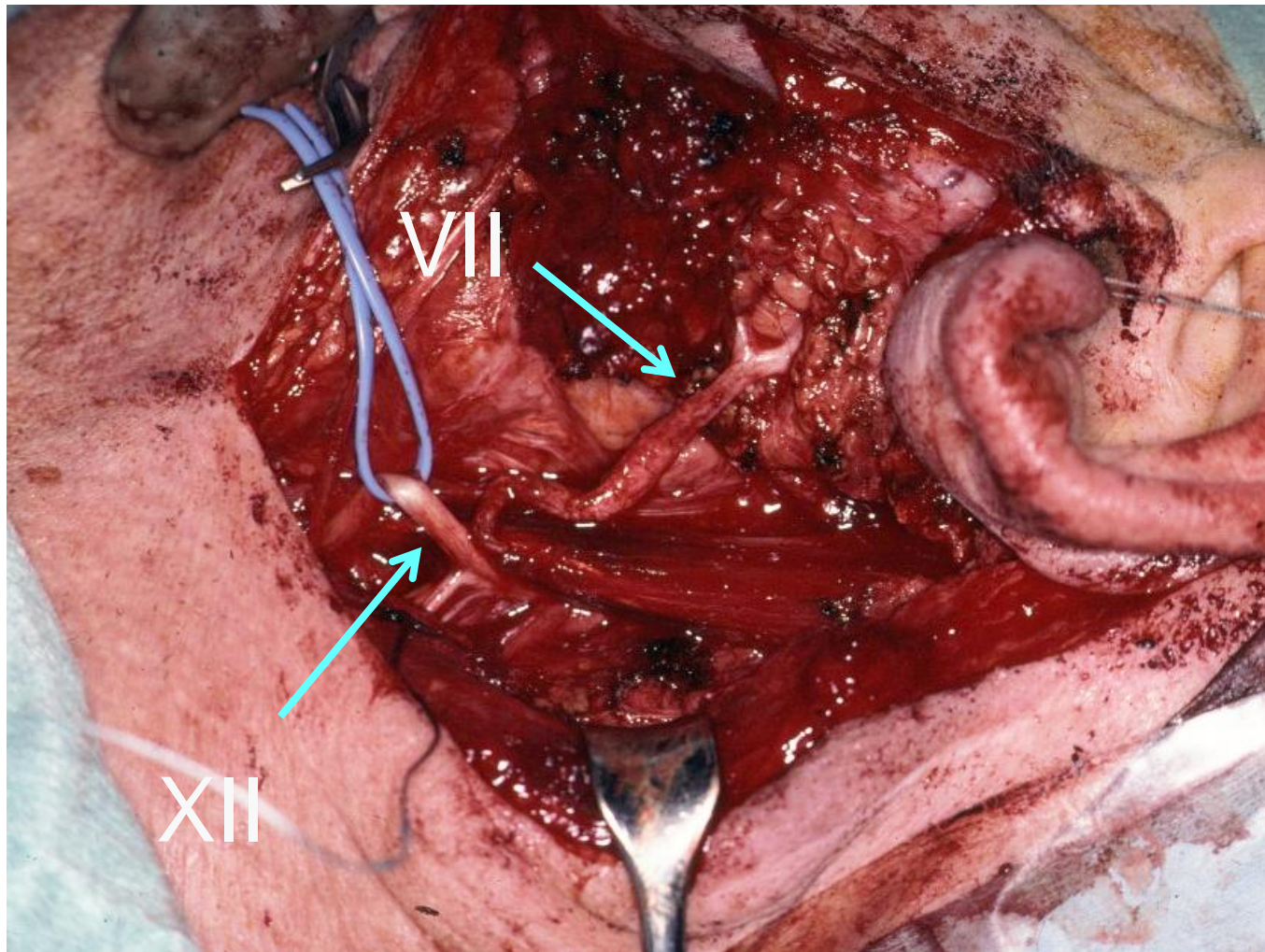


# VII-VII COMBINED WITH END TO SIDE XII-VII NERVE GRAFTING



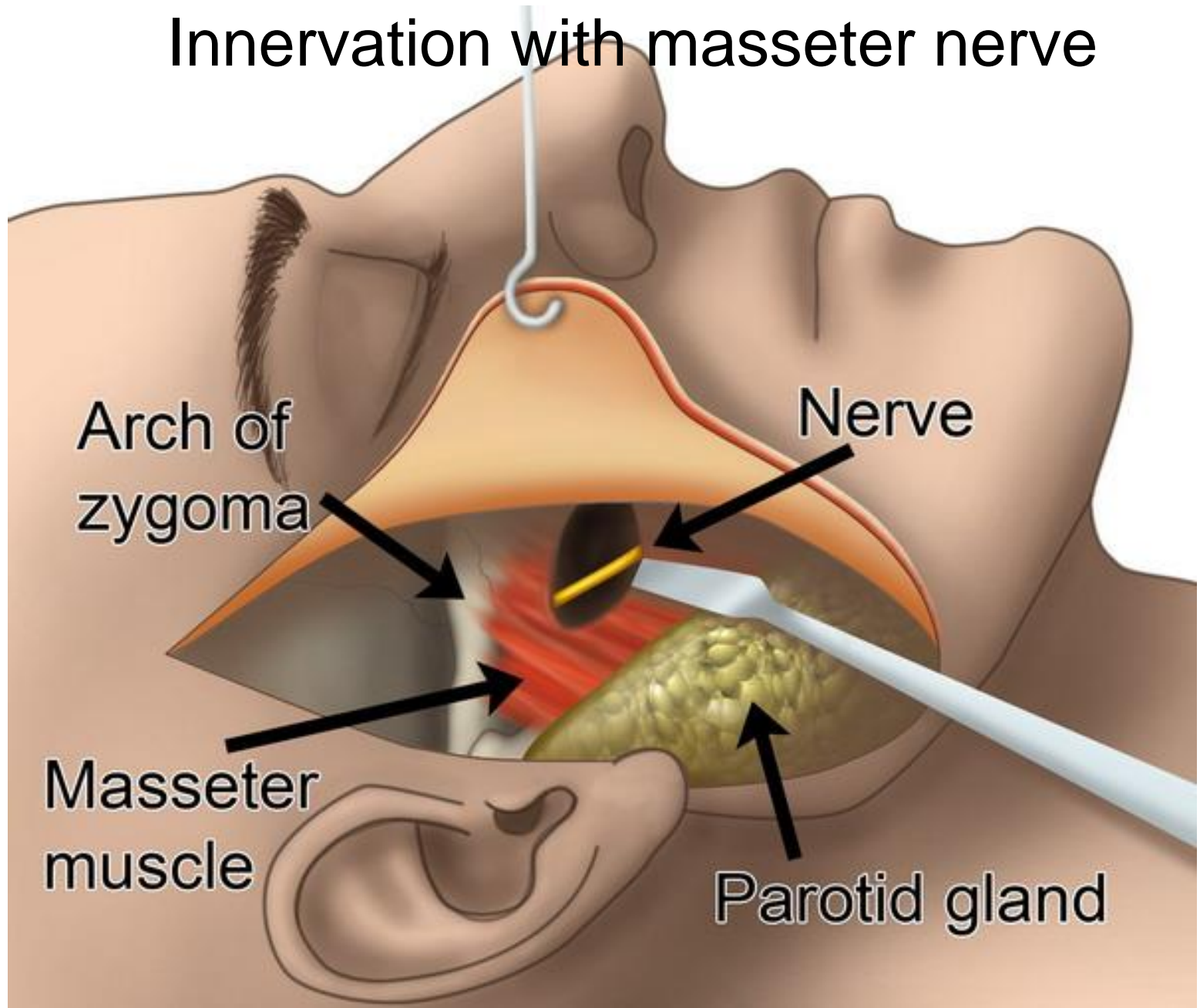


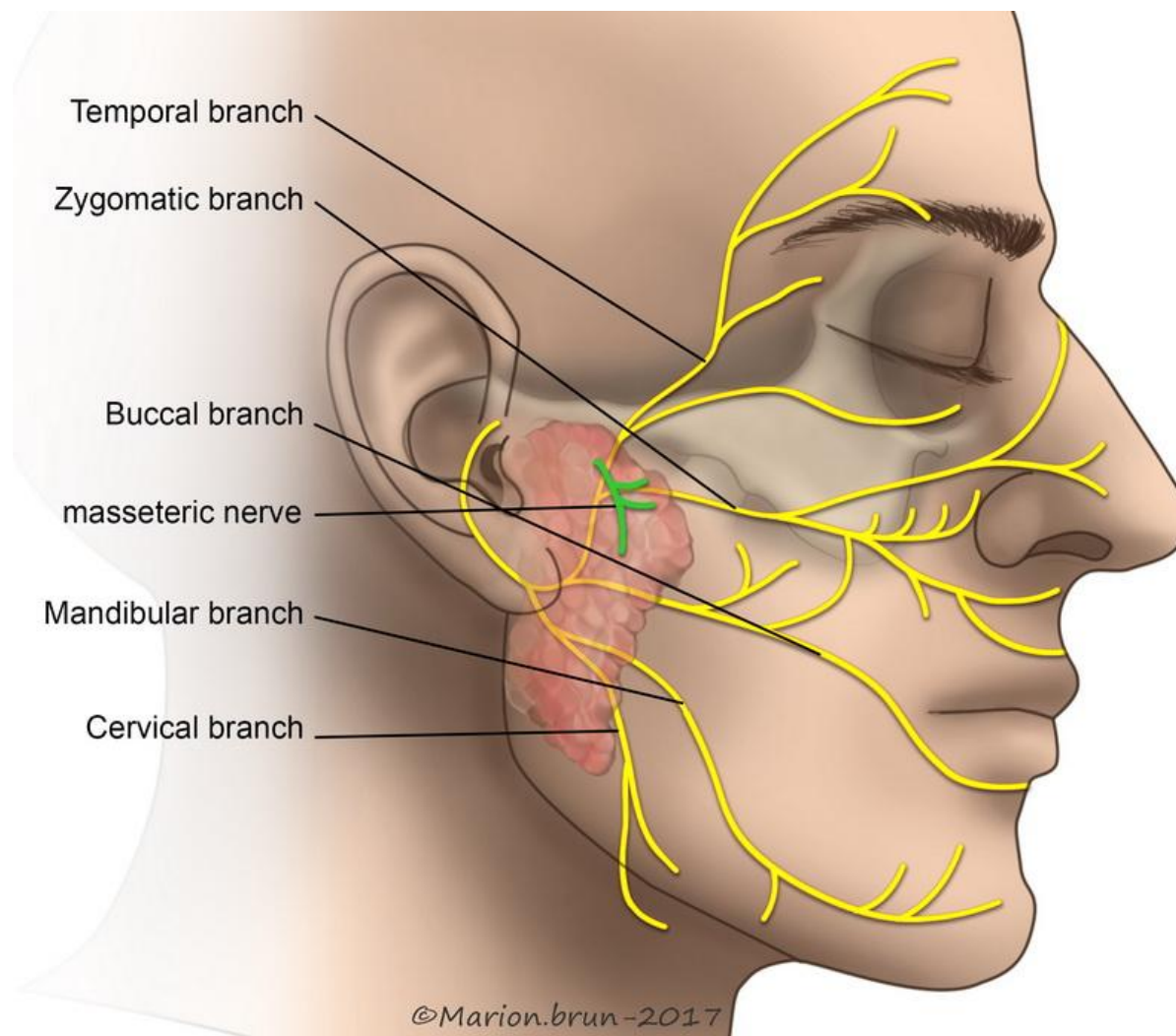
# LEFT XII –VII WITH INTRAMASTOID VII TRANSPOSITION

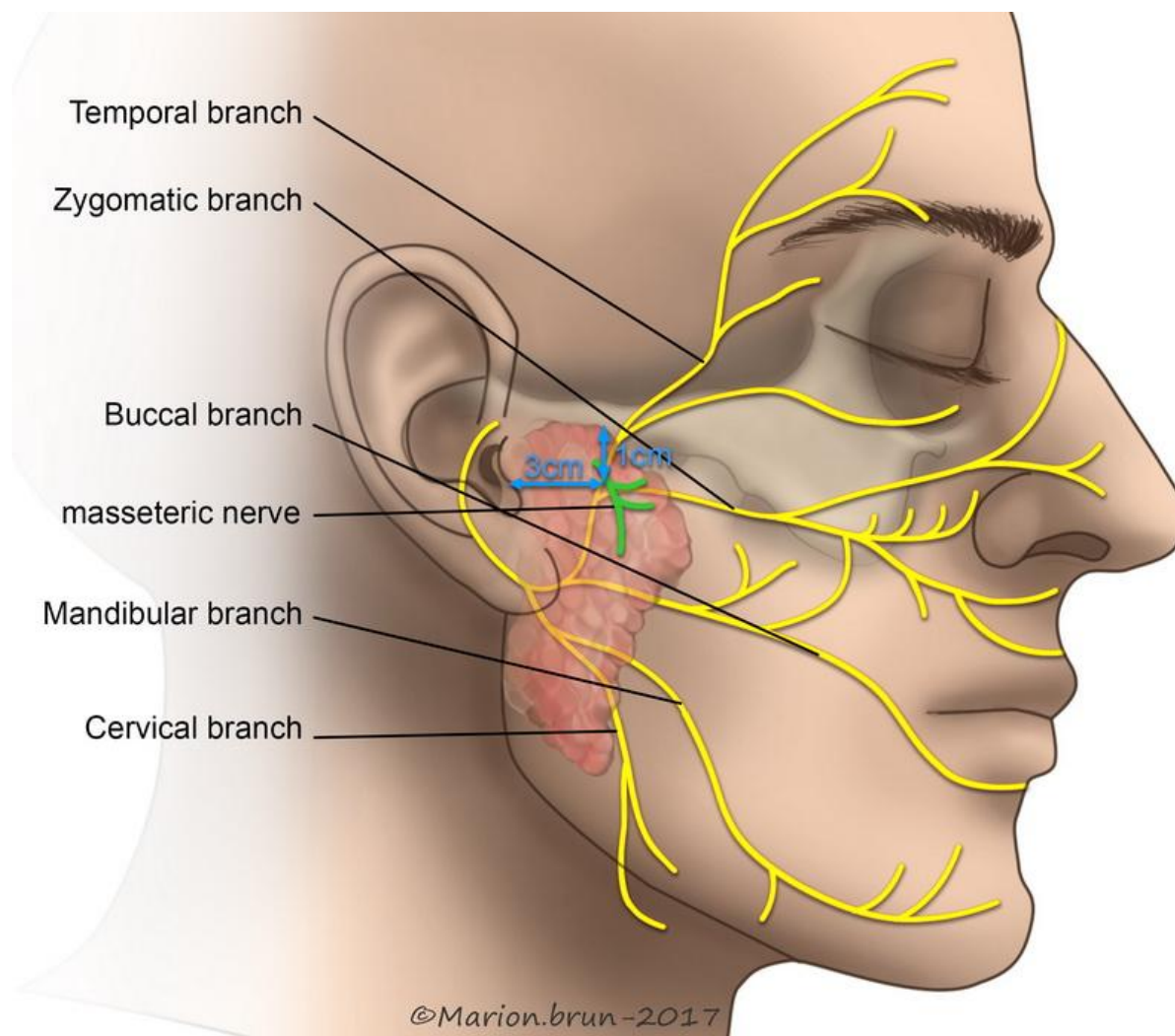


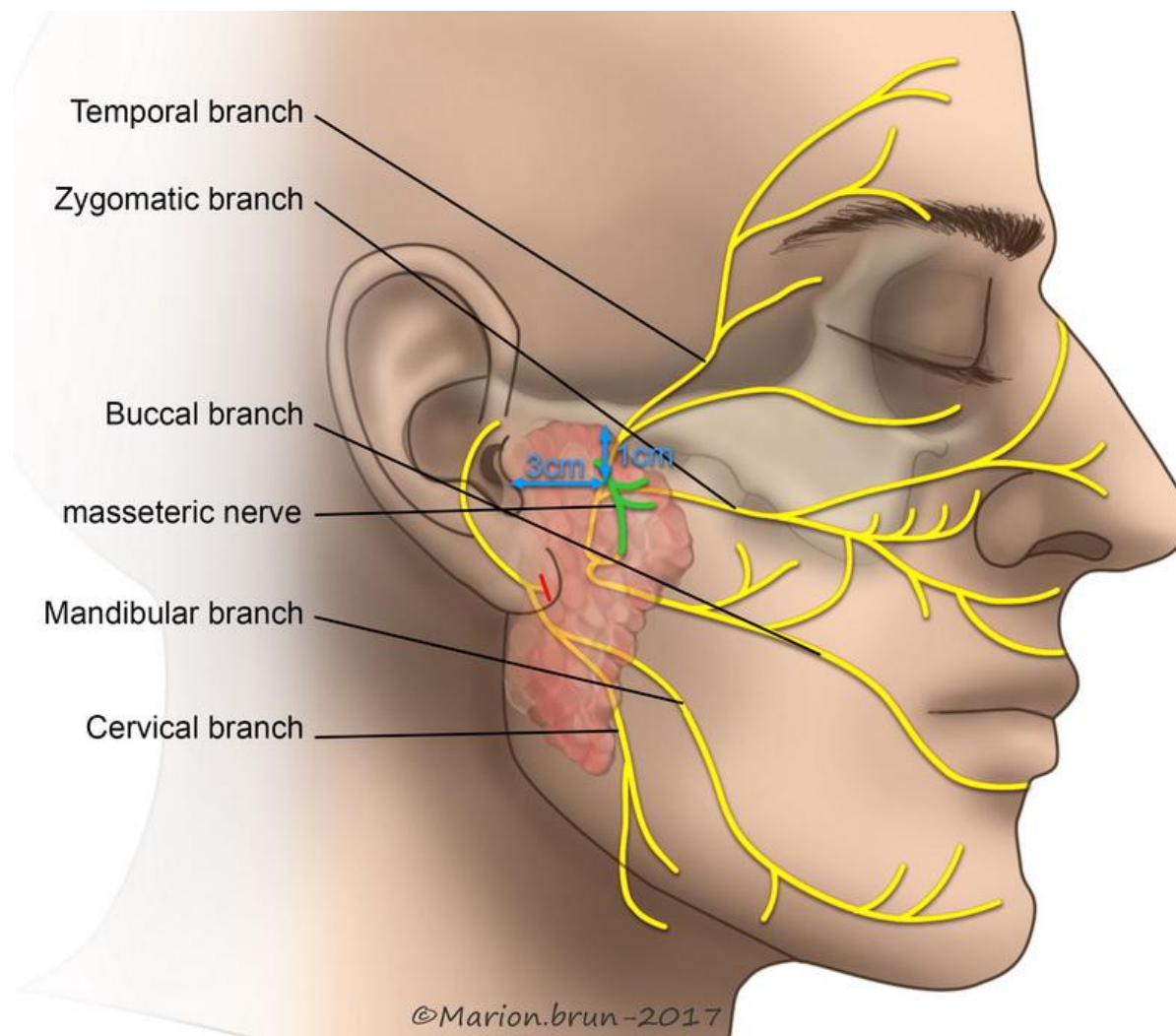


# Innervation with masseter nerve

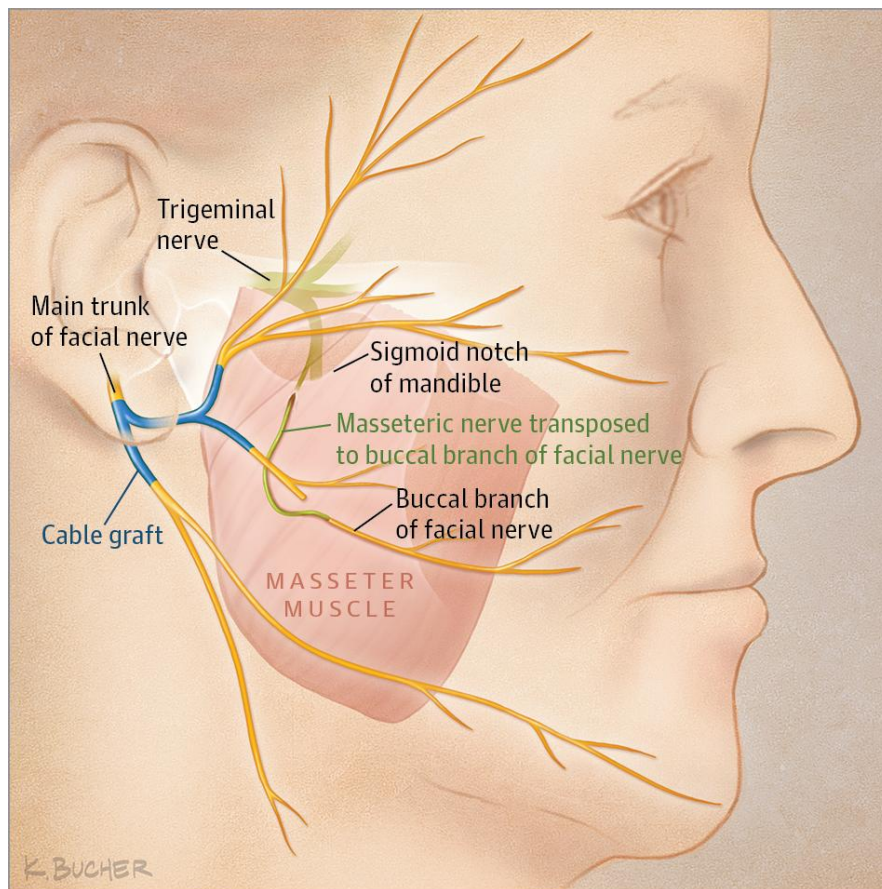






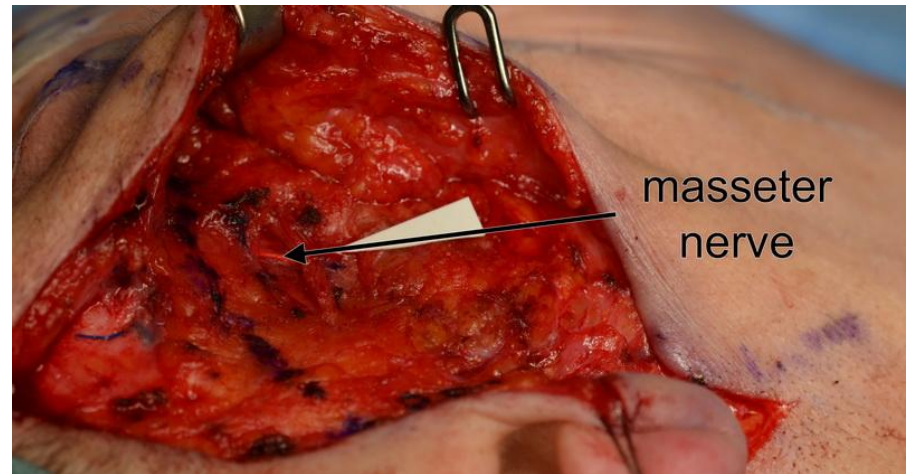
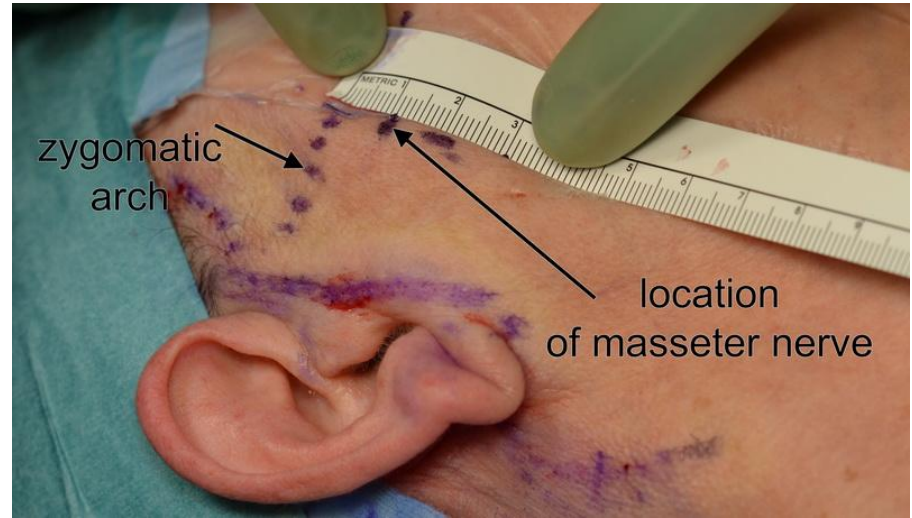
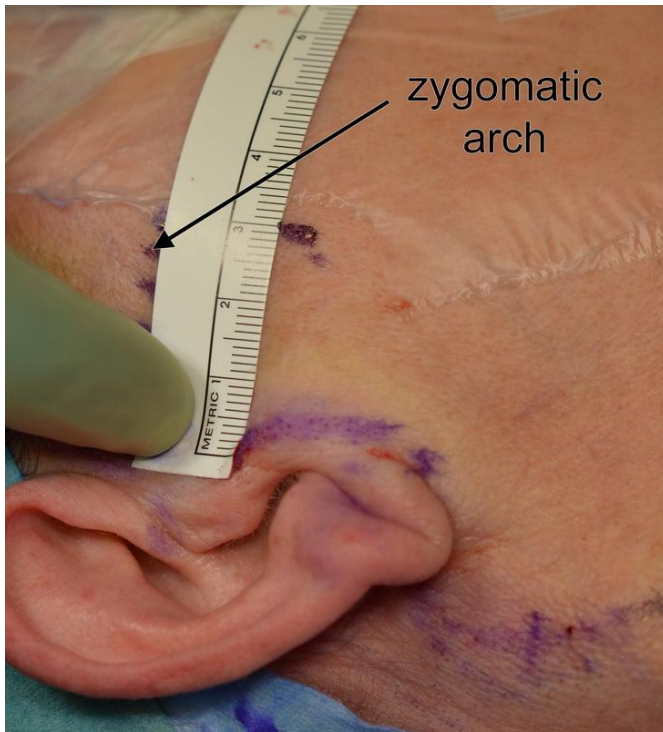






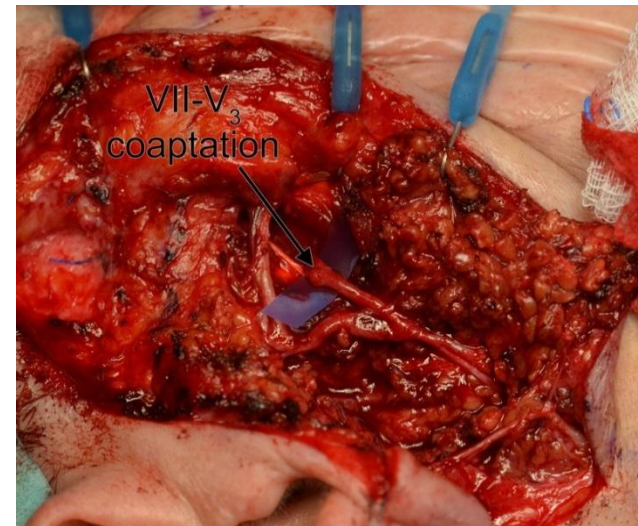
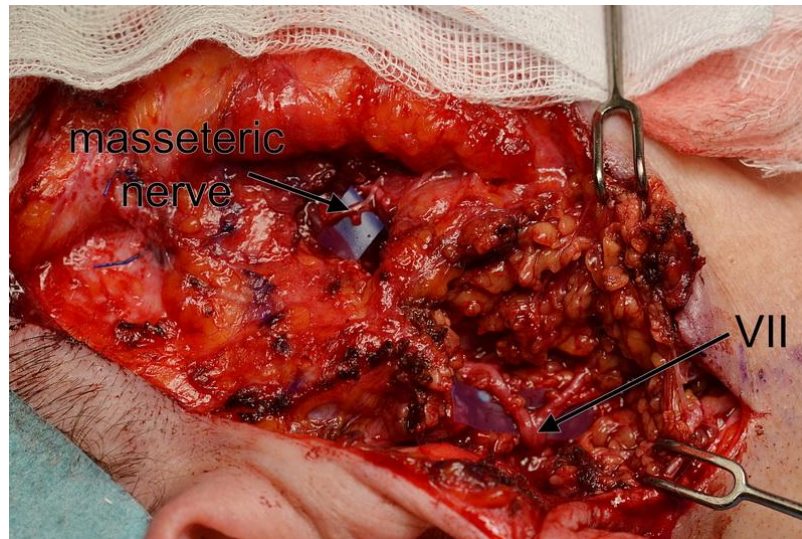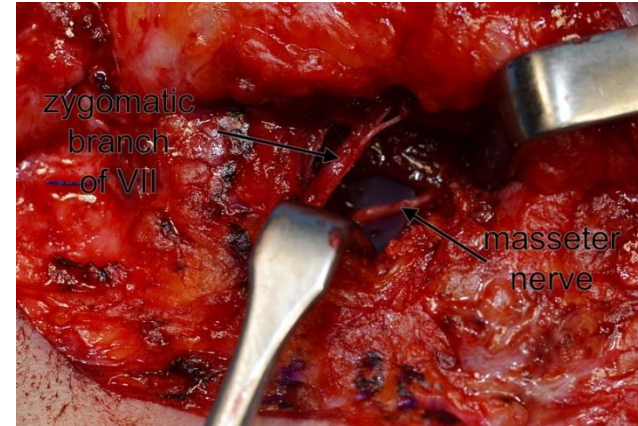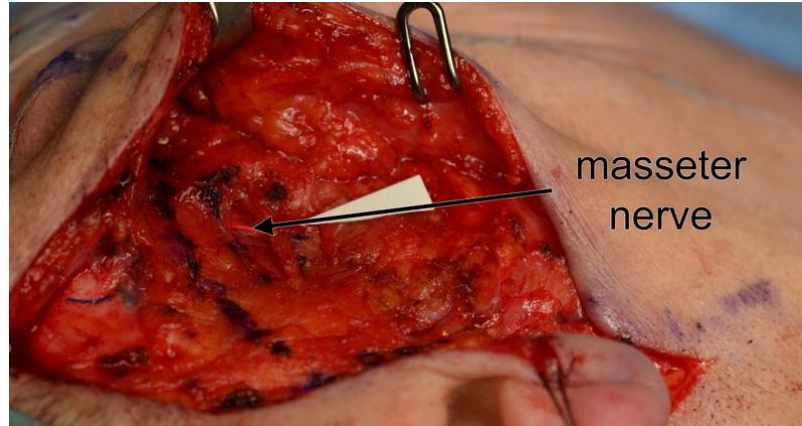
Facial Nerve Reconstruction With Concurrent Masseteric Nerve Transfer and Cable Grafting.  
J. OWUSU et al. JAMA Facial Plast. Surg. 2016

# masseter nerve (V2)





# Facial - Masseteric nerve coaptation (VII – V<sub>3</sub>)



# Facial nerve reconstruction with dual reinnervation

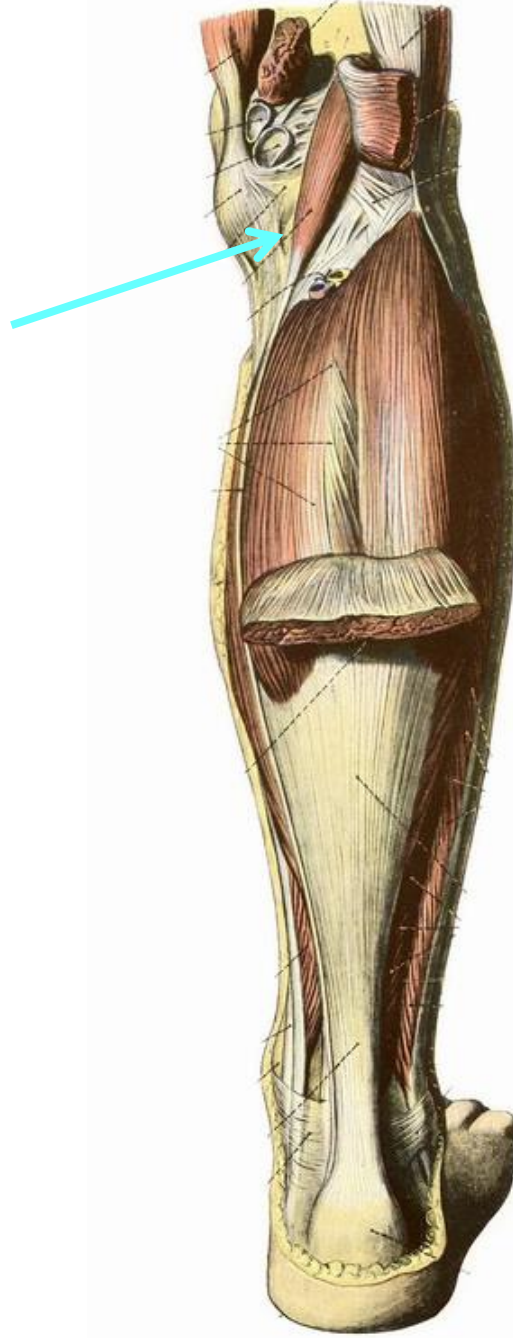
- VII promote spontaneous mouvement
- V provide rapid and strong reinnervation
- Reduce reinnervation time
- 2 separate nerve input for upper and lower face
- Reduce synkinesis

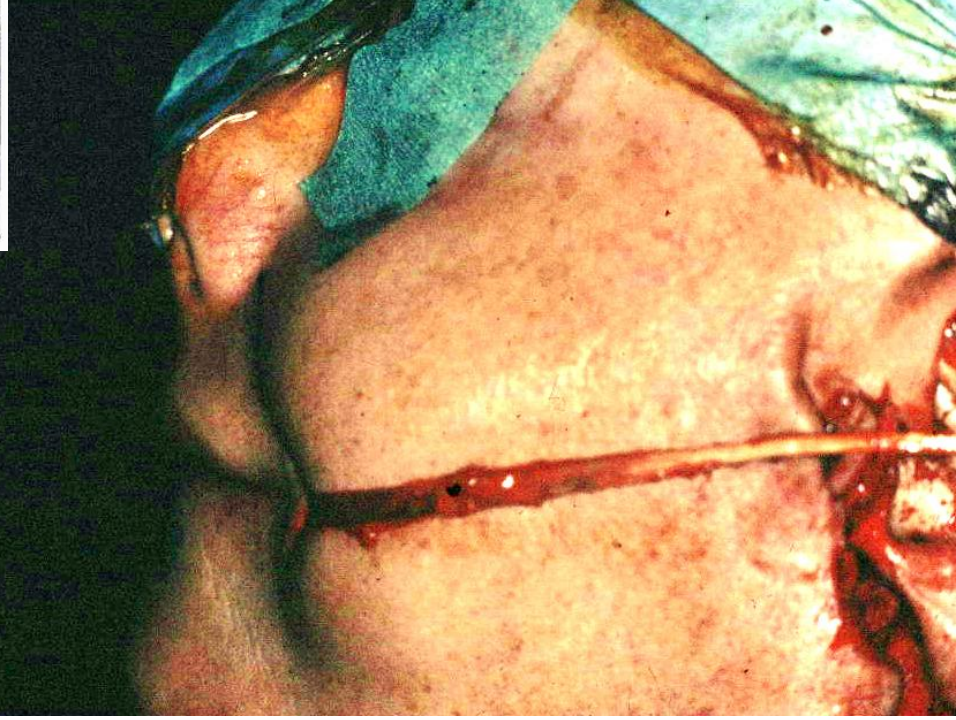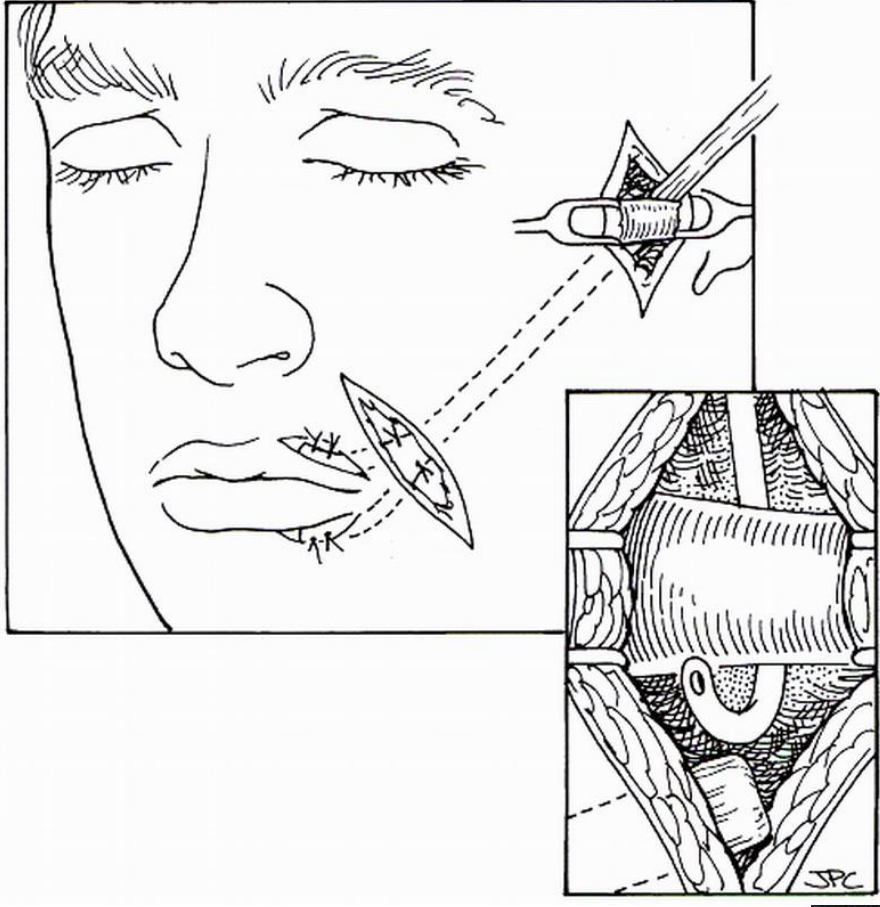


# Static suspension

- Adjunctive tool
- Fascia lata , plantar tendon, palmar tendon
- Combined with nerve graft
- Combine with masseteric nerve
  - Direct neuroraphy
  - Gracilis innervated with V

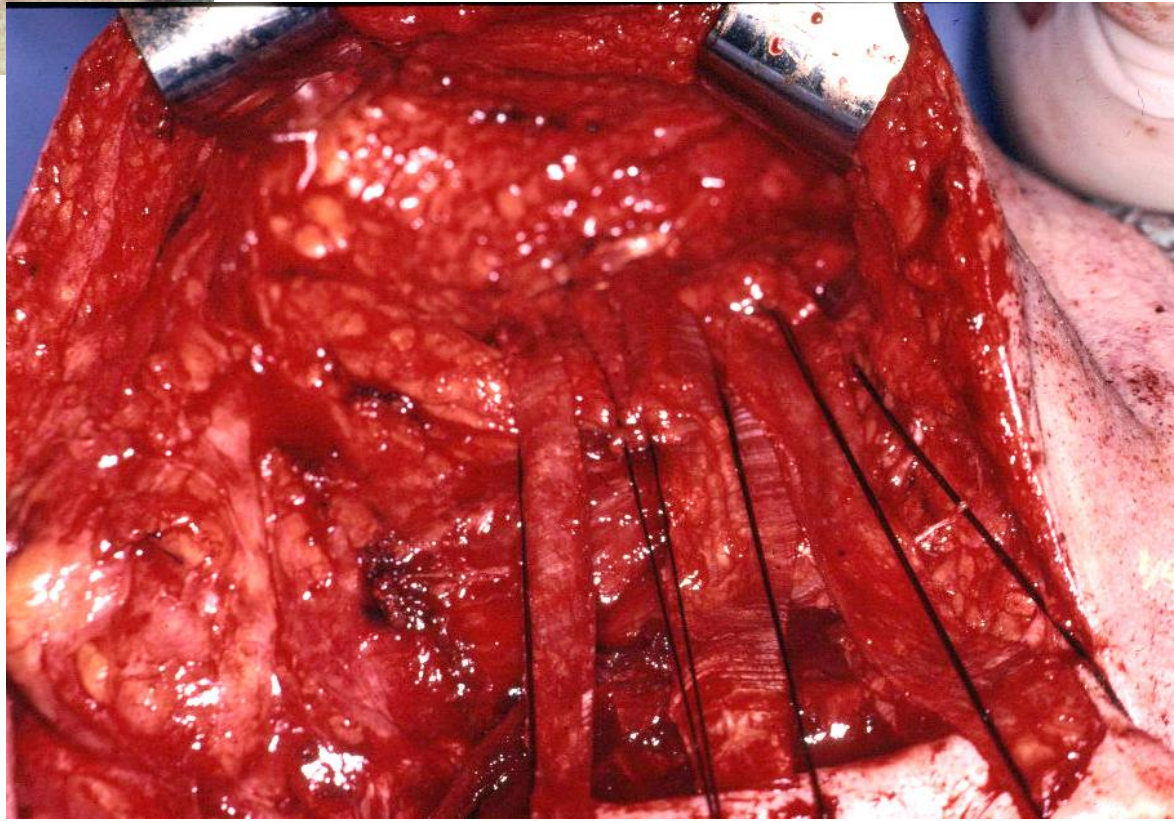
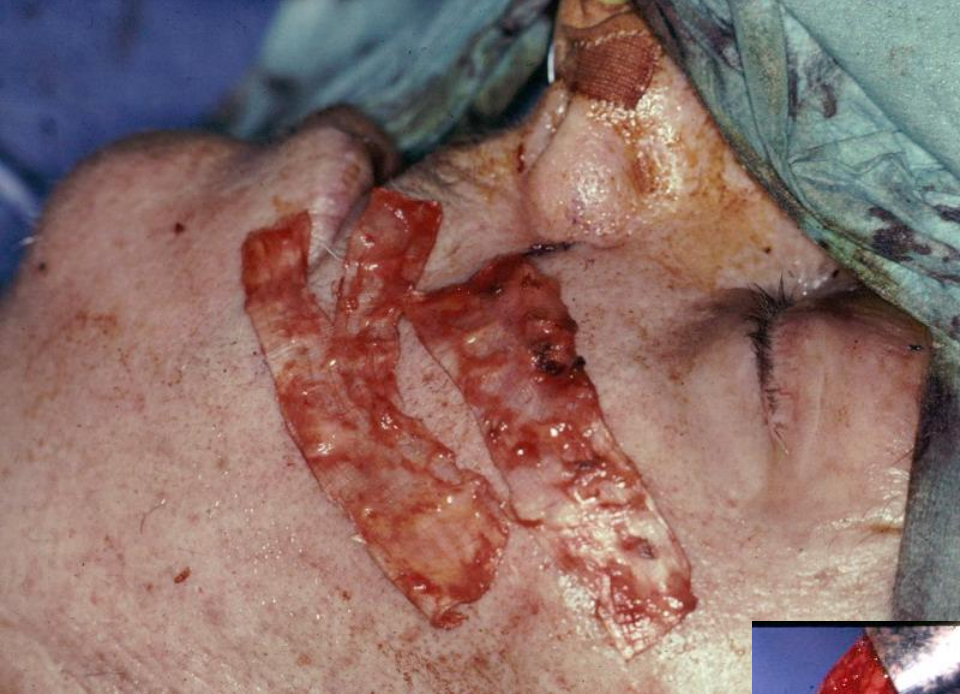# Plantar muscle



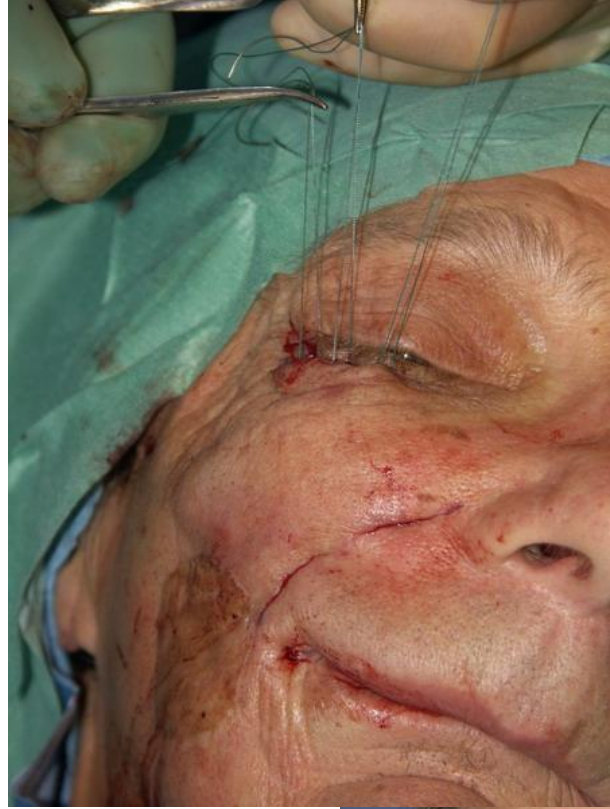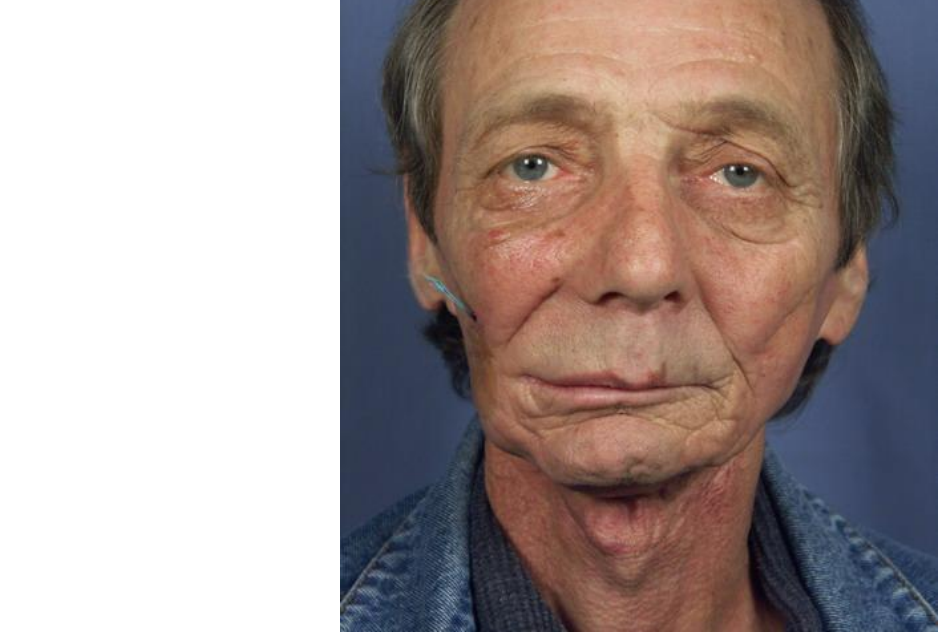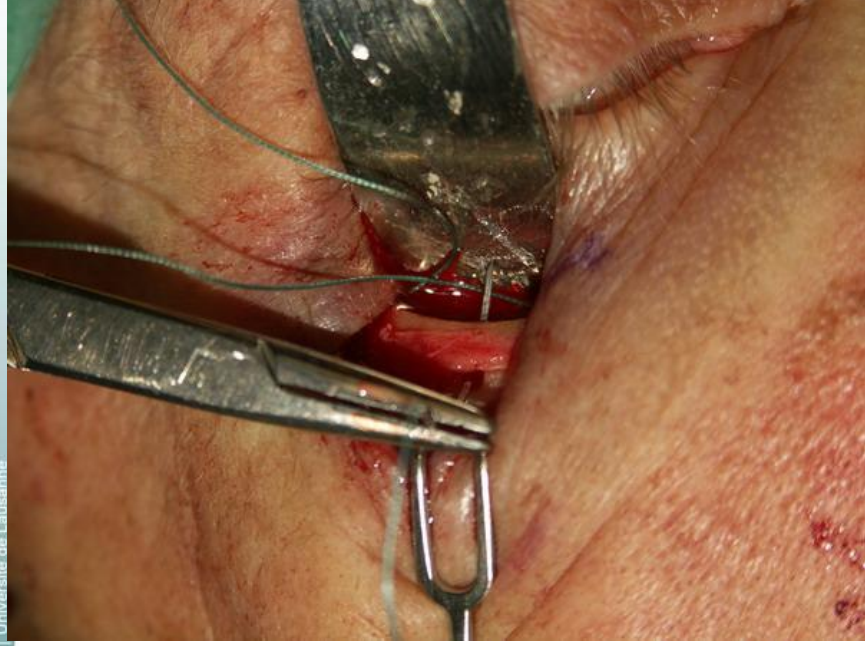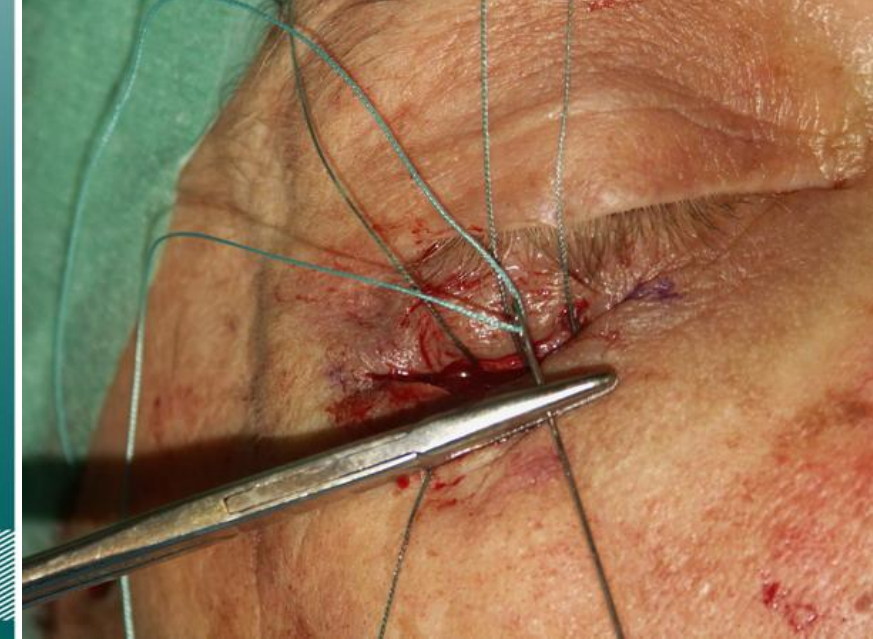




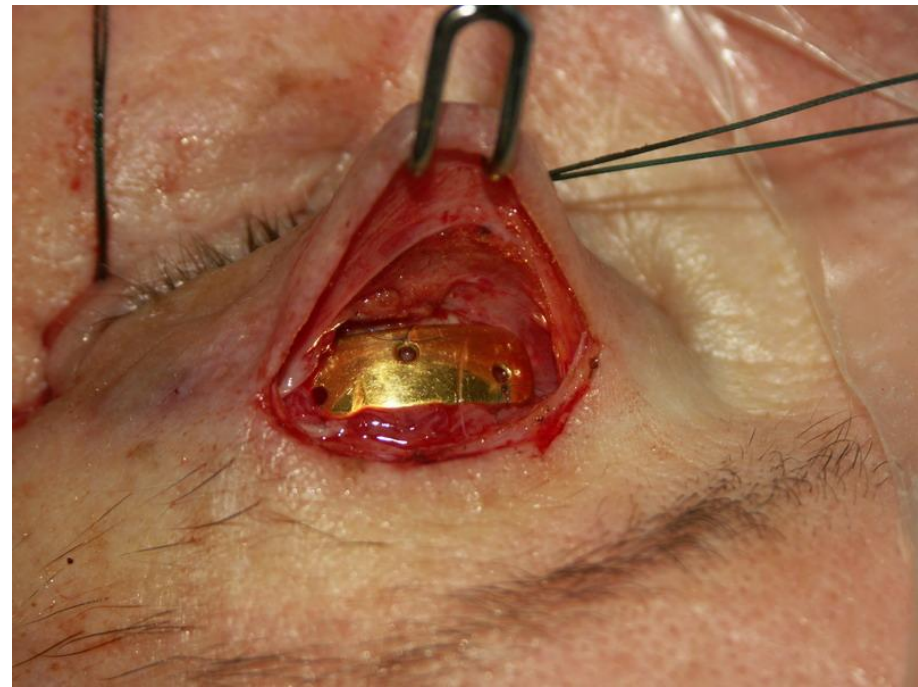
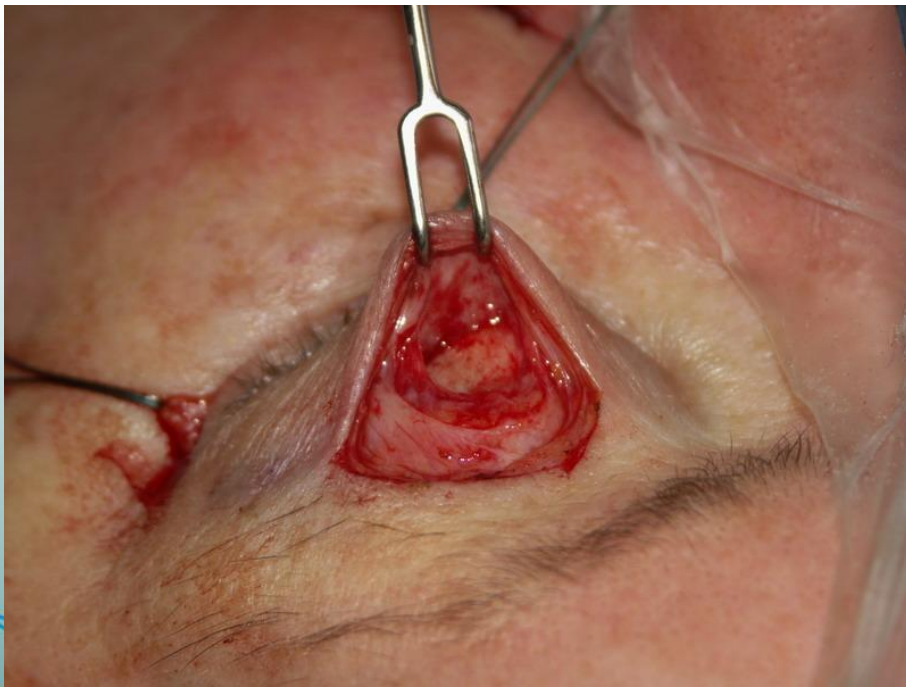
# Static suspension with facia lata during parotid surgery



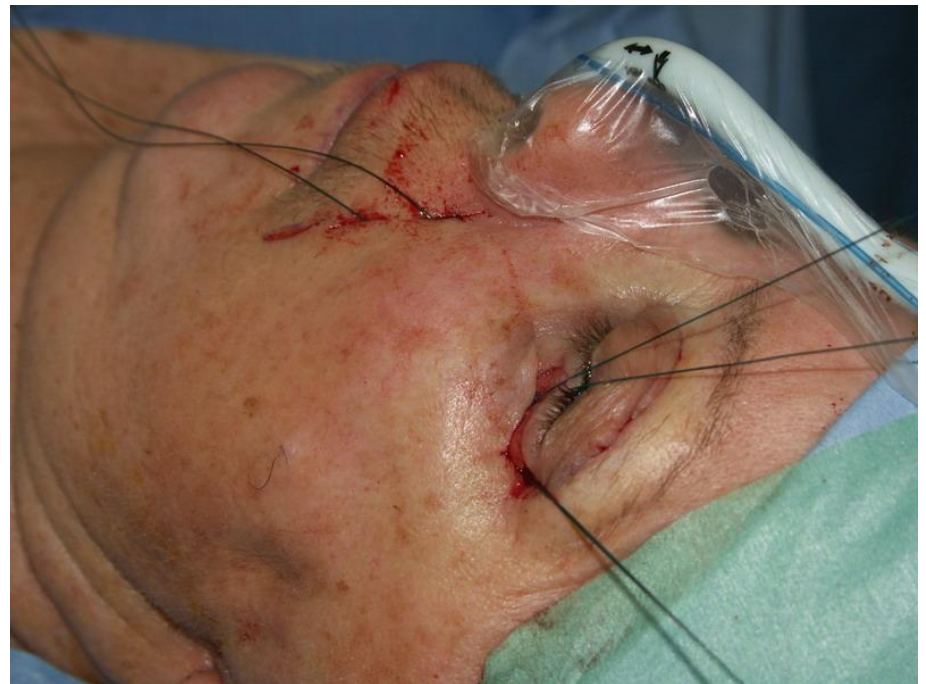





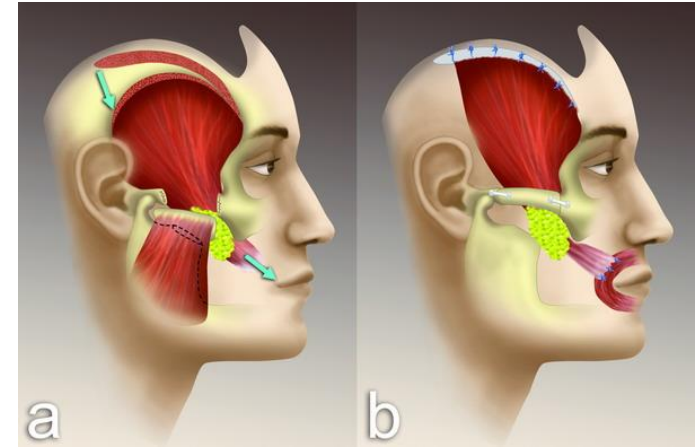


Static suspension  
with multiple  
permanent sutures  
Lateral cantoplasty  
and gold implant



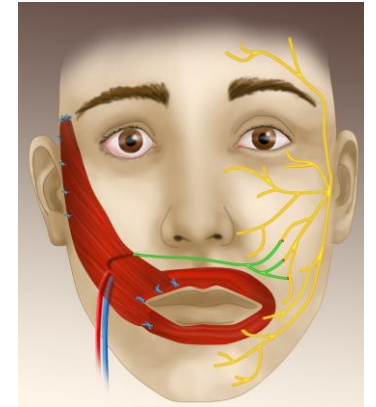
# Dynamic smile reanimation with muscle transfert

- Temporal myoplasty (V3)

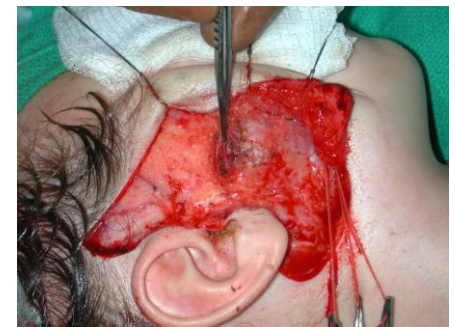

- Free muscle transfert

- Two stages: cross-face (VII) + muscle transfert

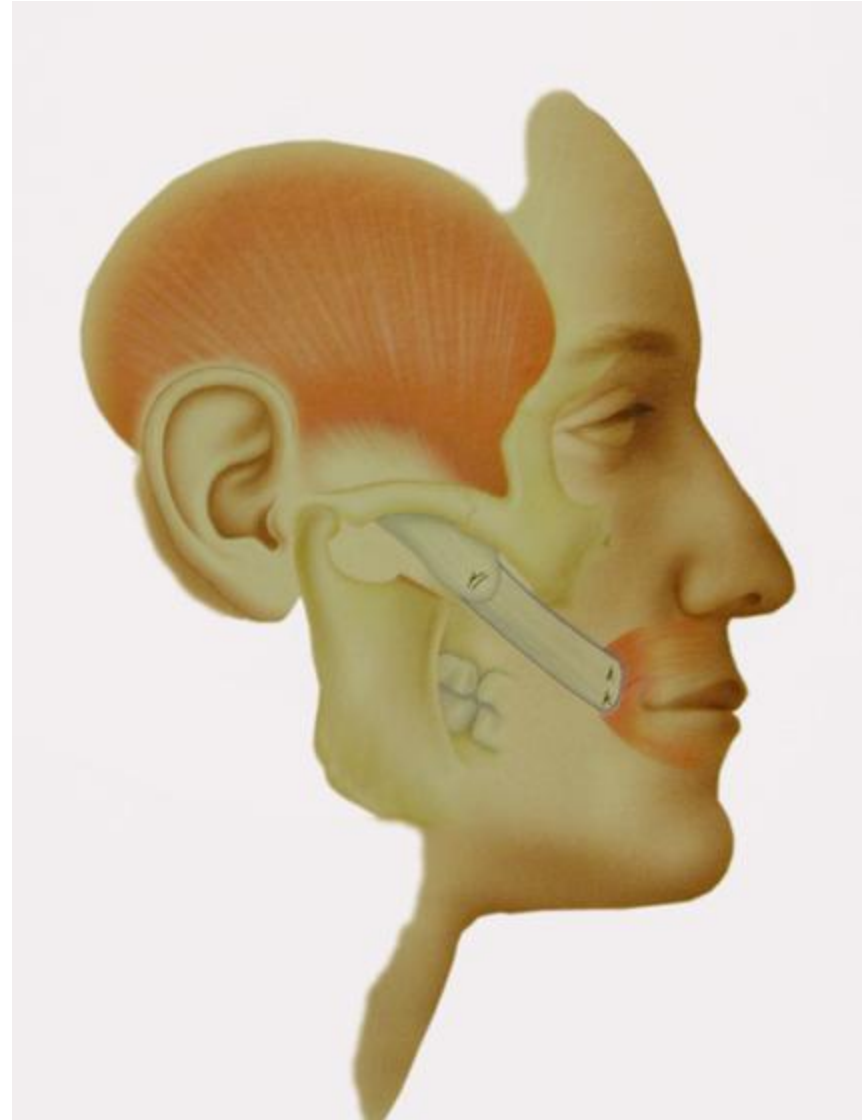


- One stage with masseteric nerve grafting (V)



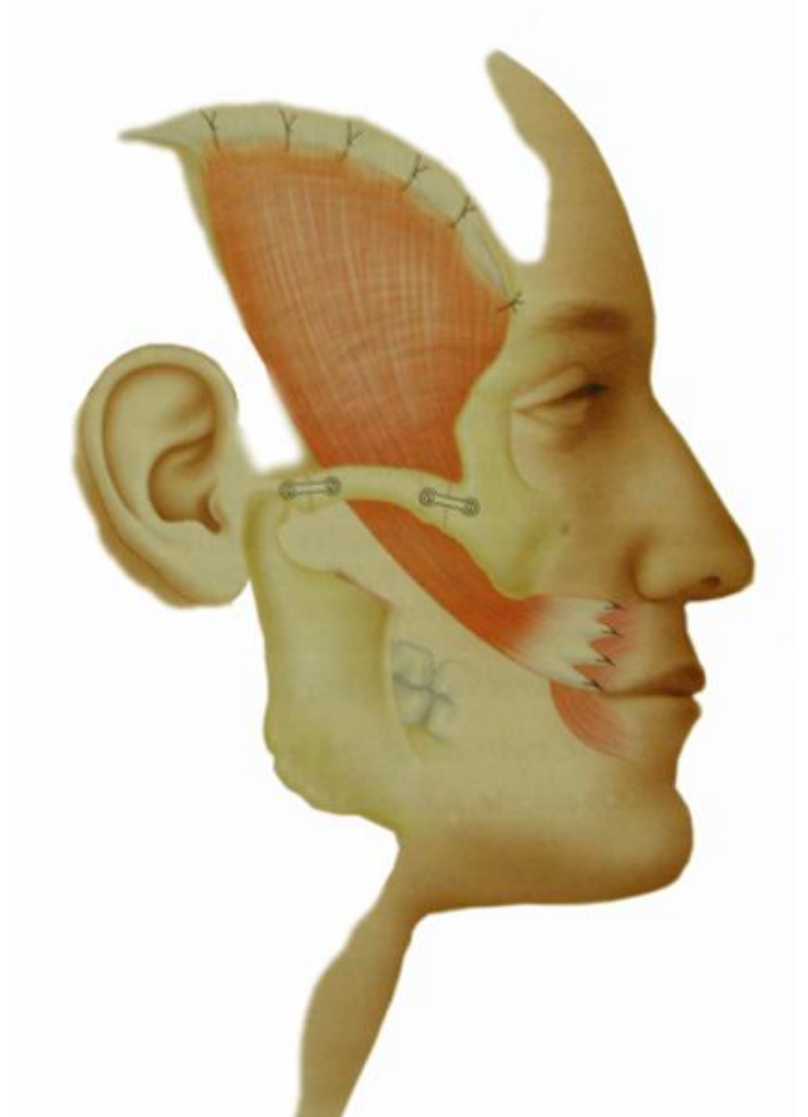
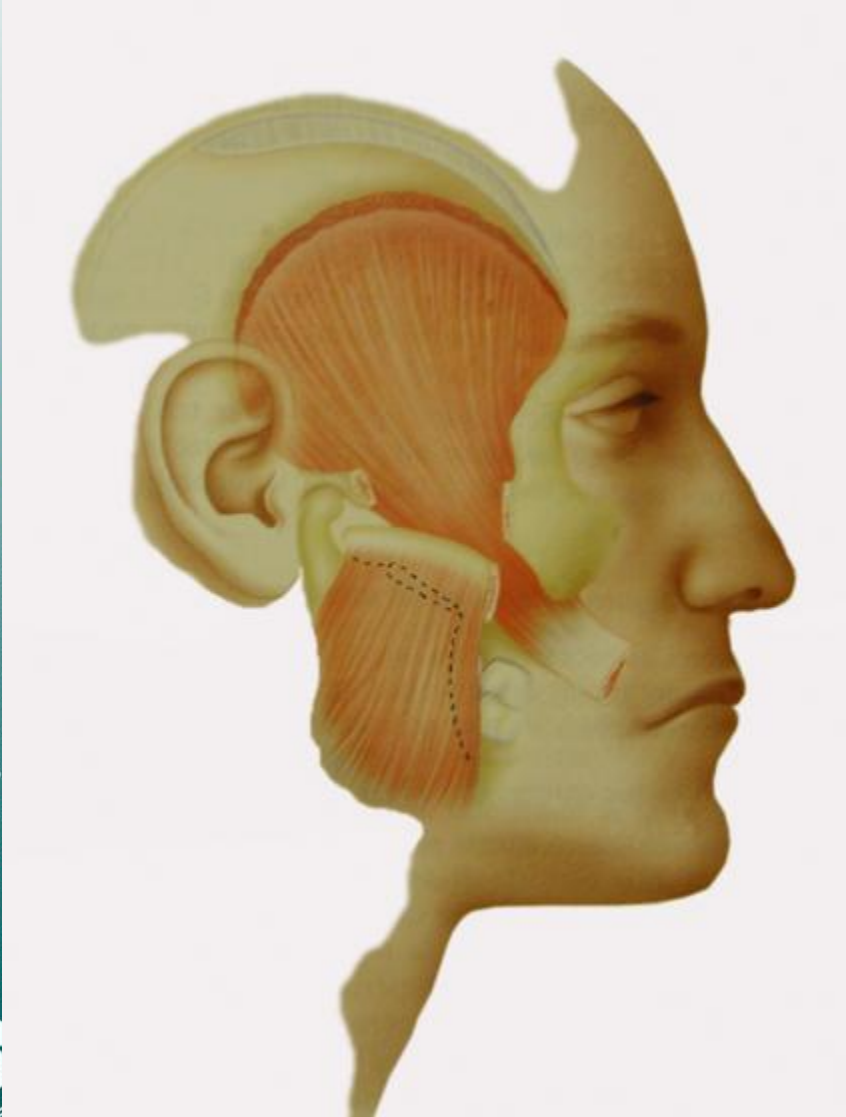
# Temporal myoplasty

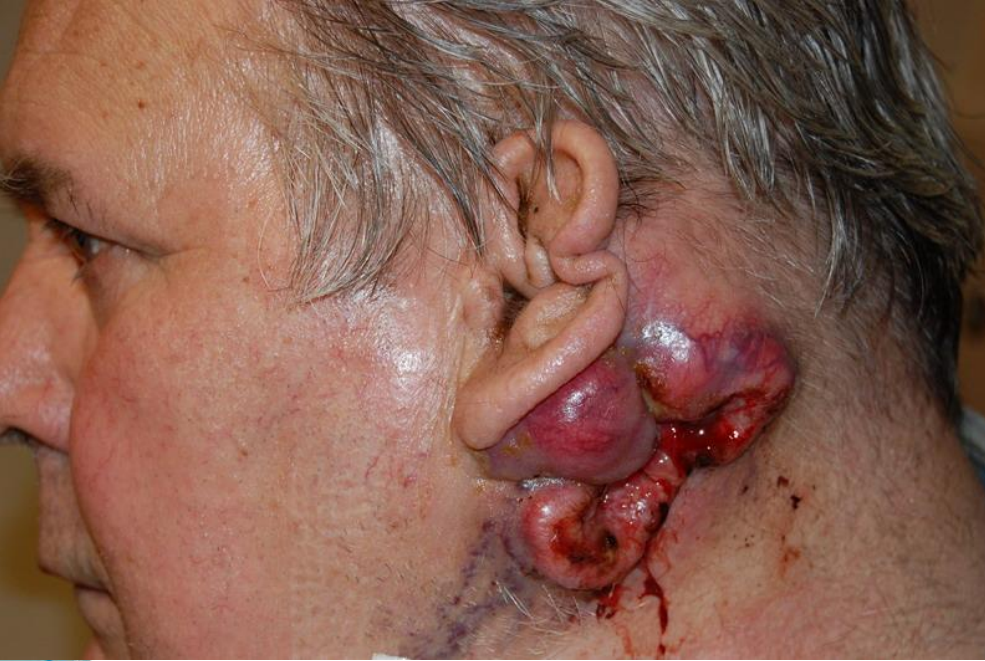Mc Laughlin:  
With facia lata



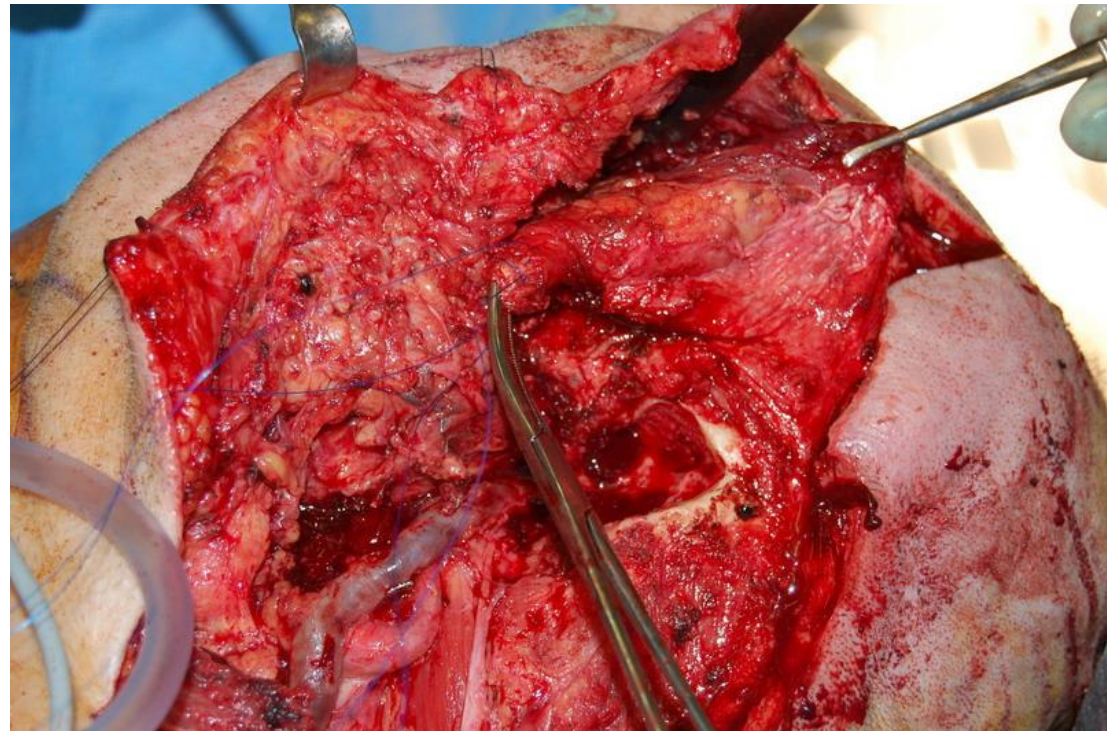


# Labbé myoplasty





SCC of the retroauricular  
area with facial nerve  
infiltration



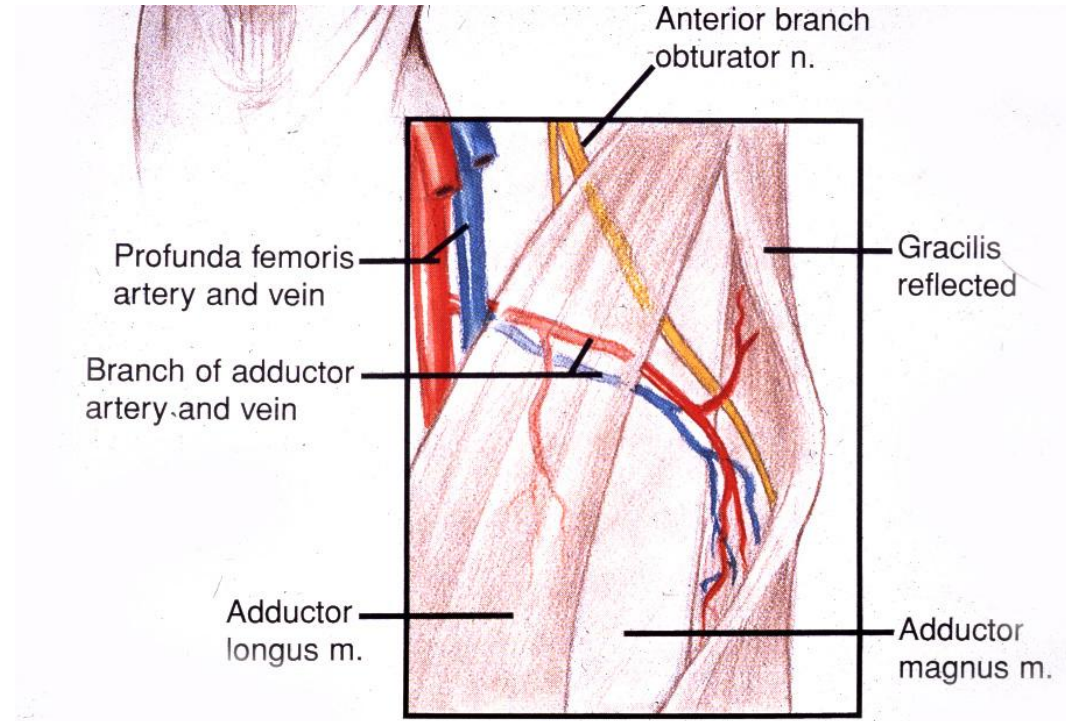
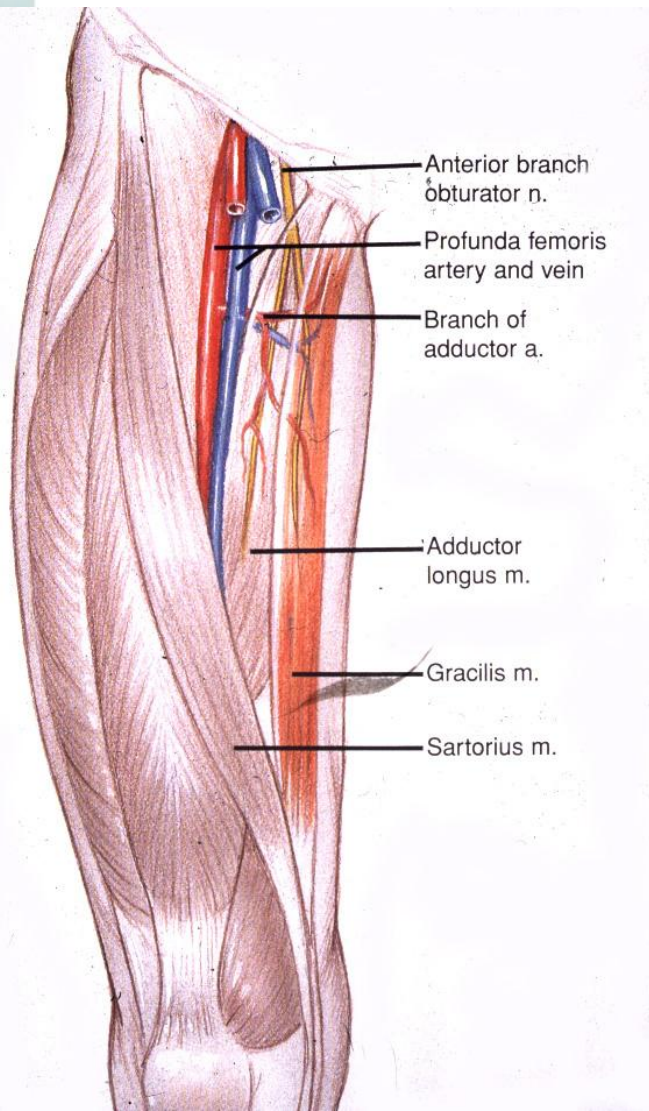
Intaoperative temporal  
muscle myoplasty

# Gracilis muscle transfert

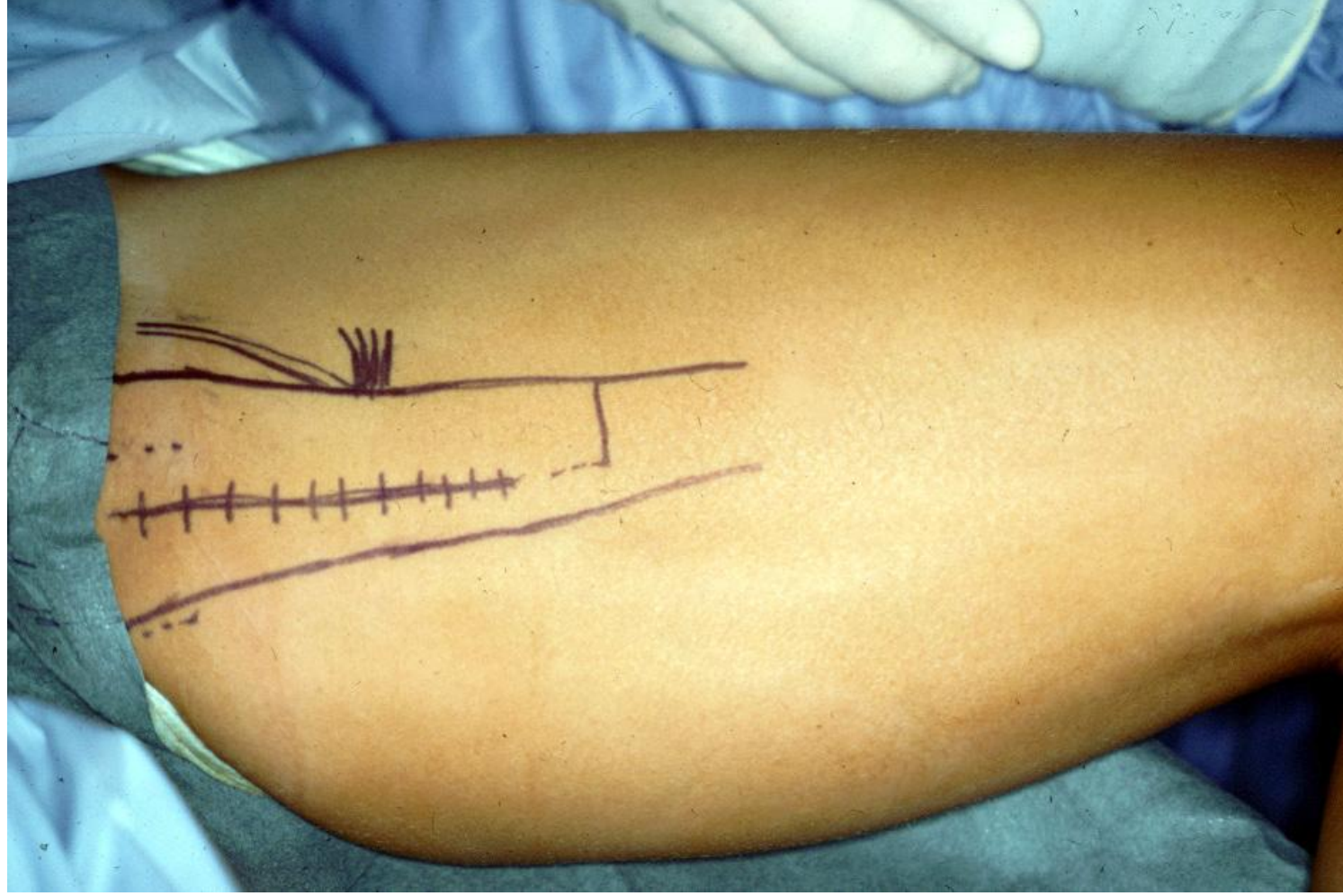
- No facial muscle
- Pre op facial palsy
- Contradication of temporal myoplasty
  - Section of V3
  - Devascularisation of the temporal muscle
- Nerve source
  - VII
  - V
  - V + CFNG (VII)

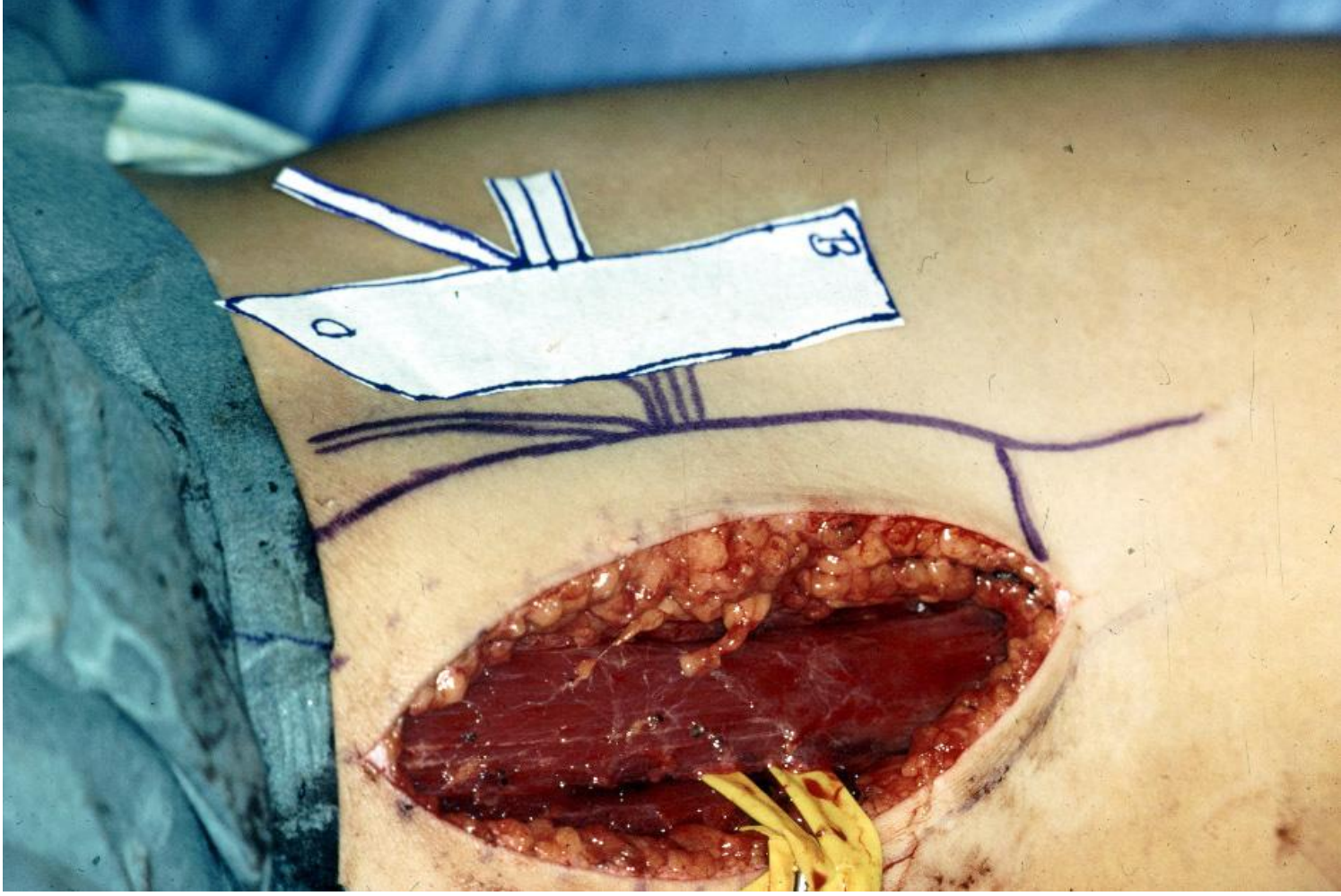


# Muscle gracilis

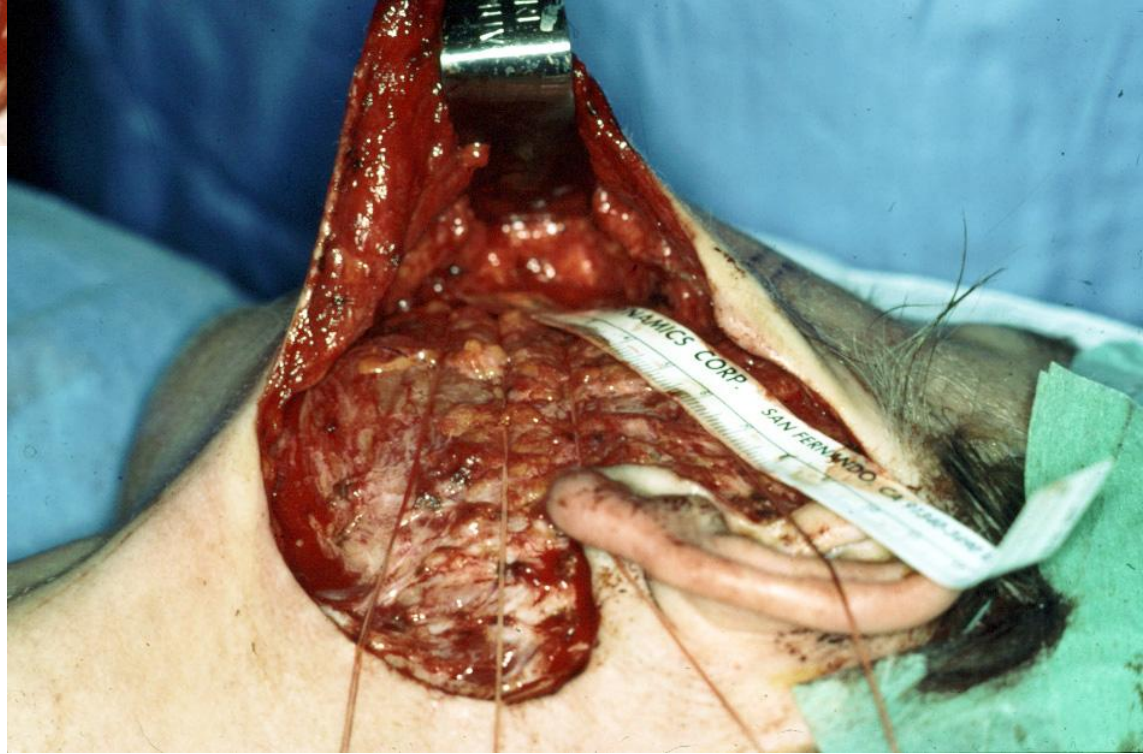
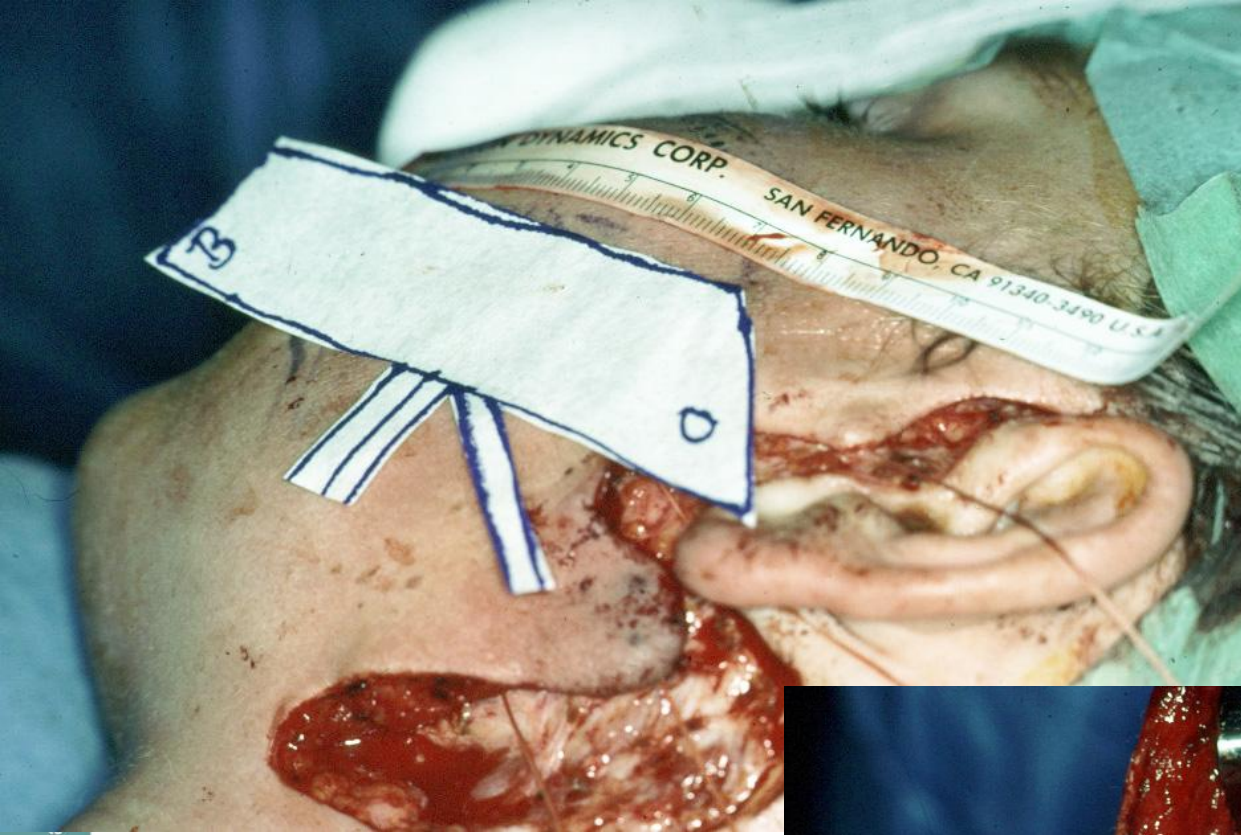




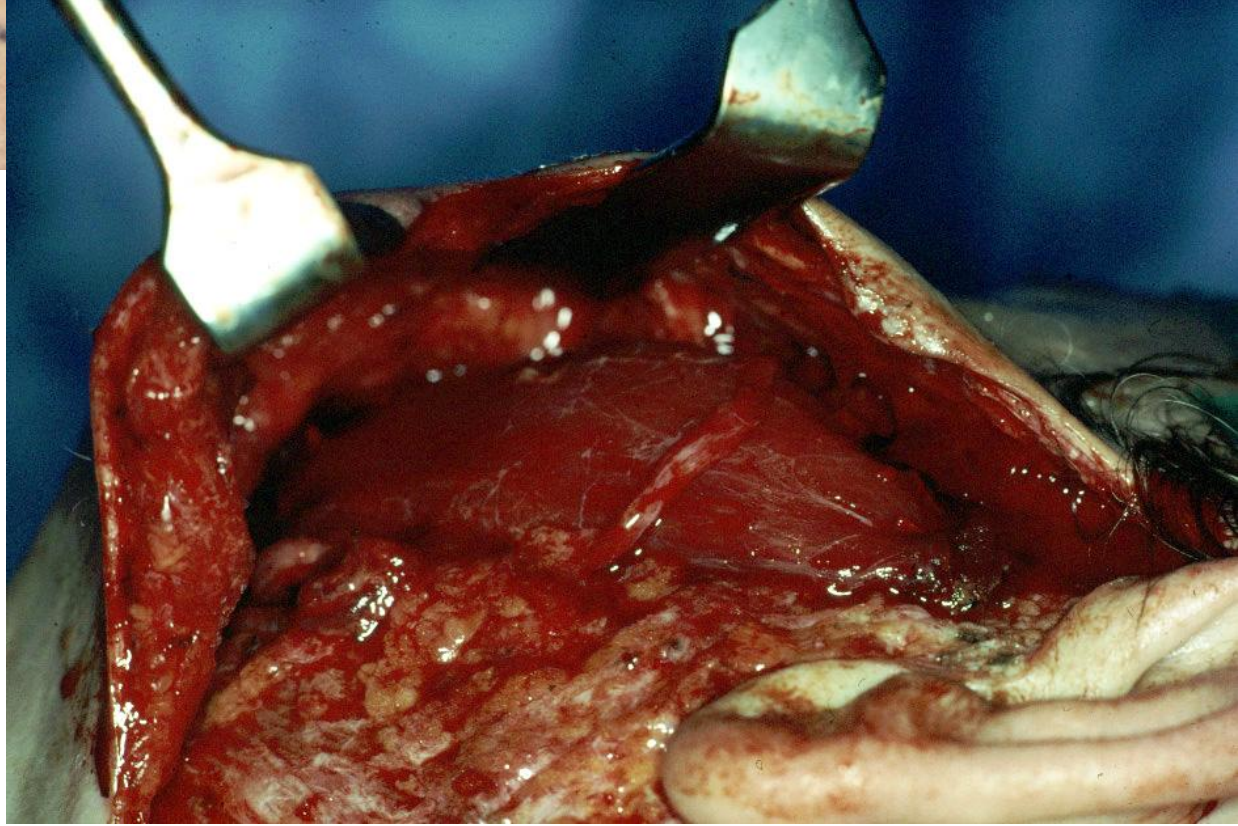
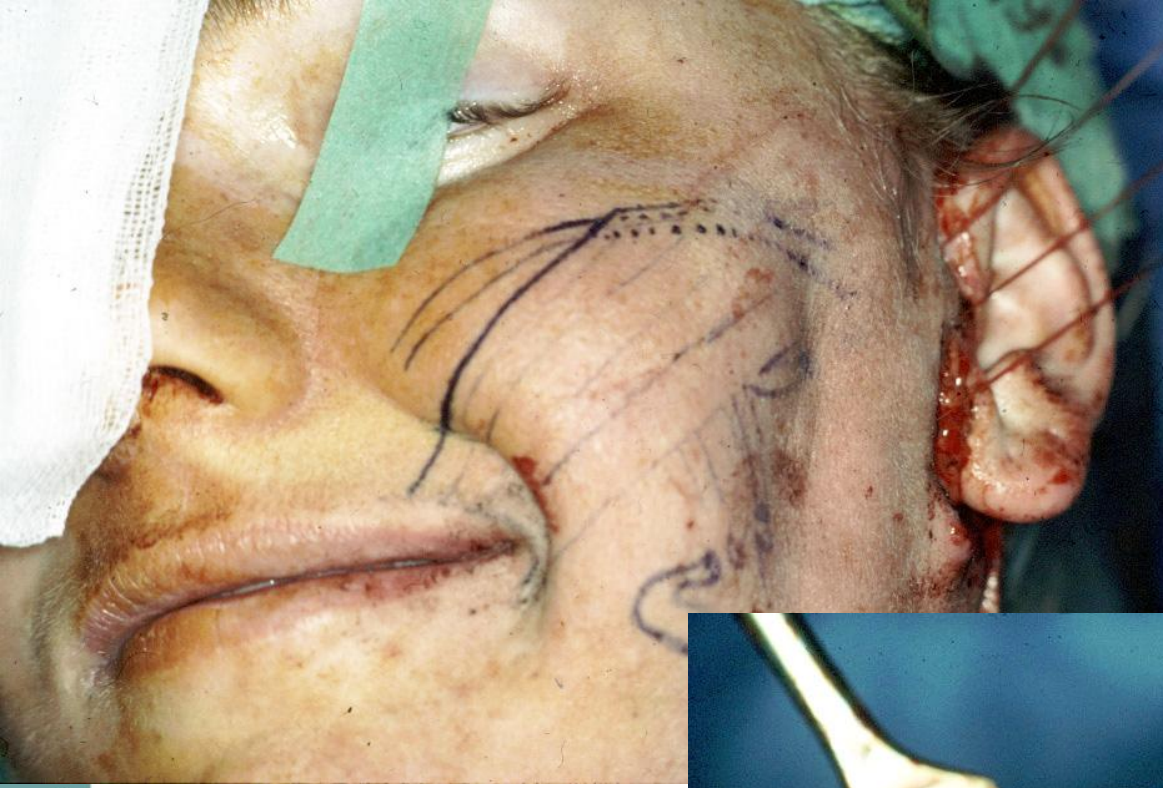





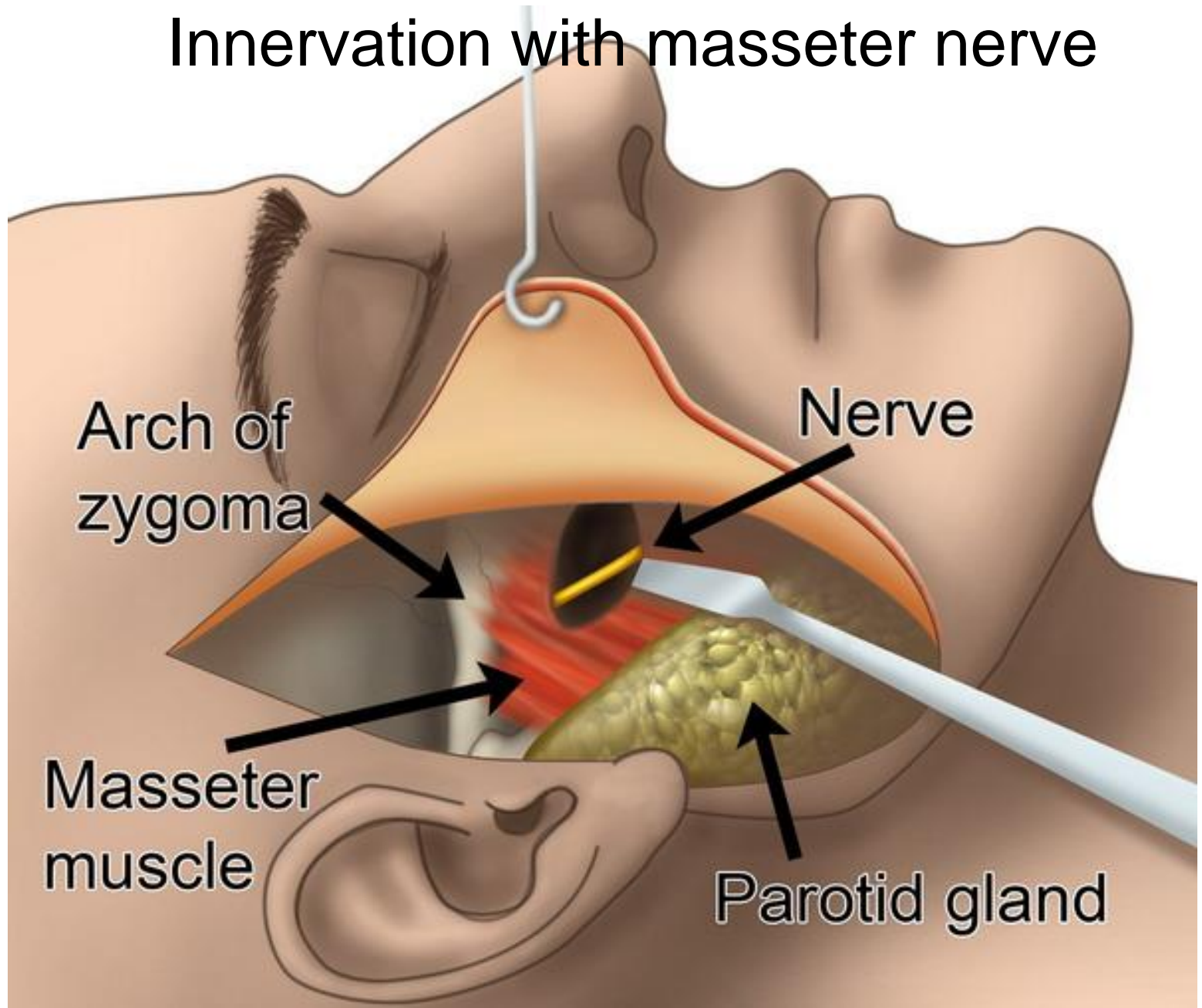


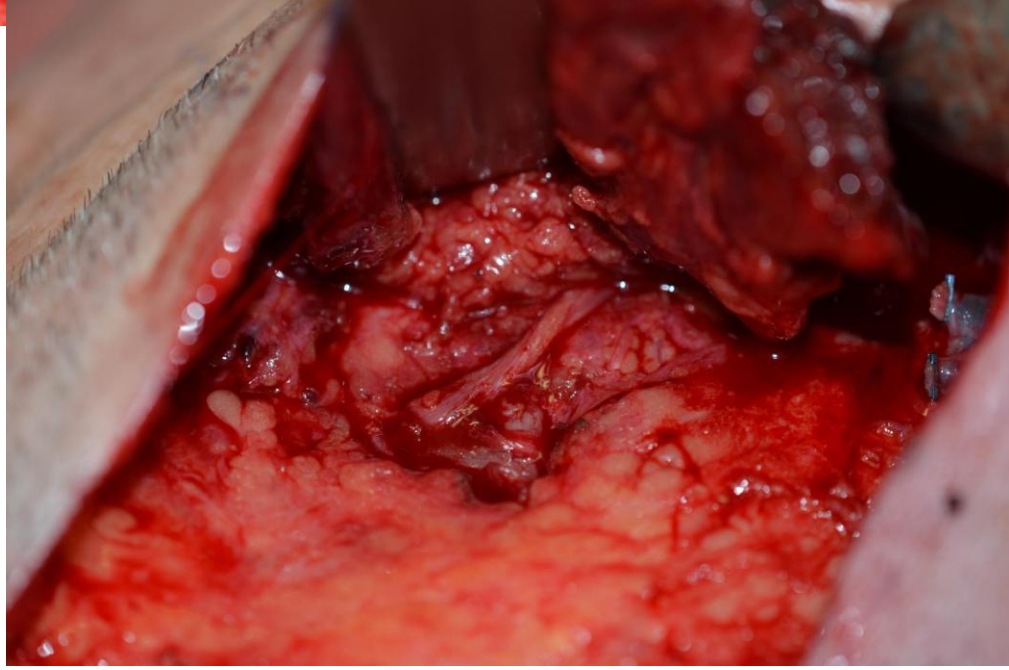
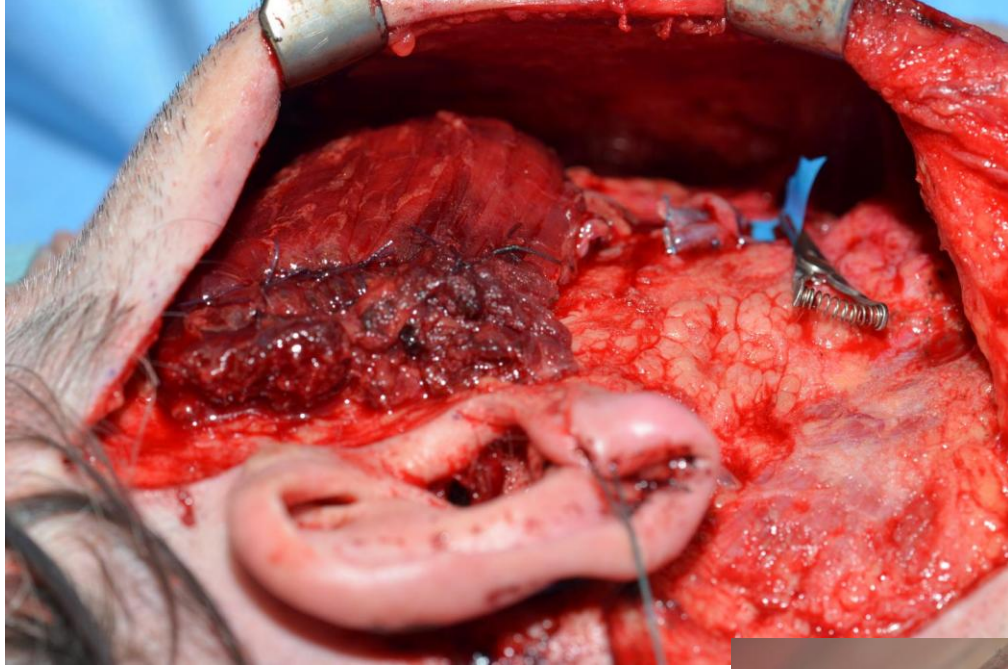






# Innervation with masseter nerve







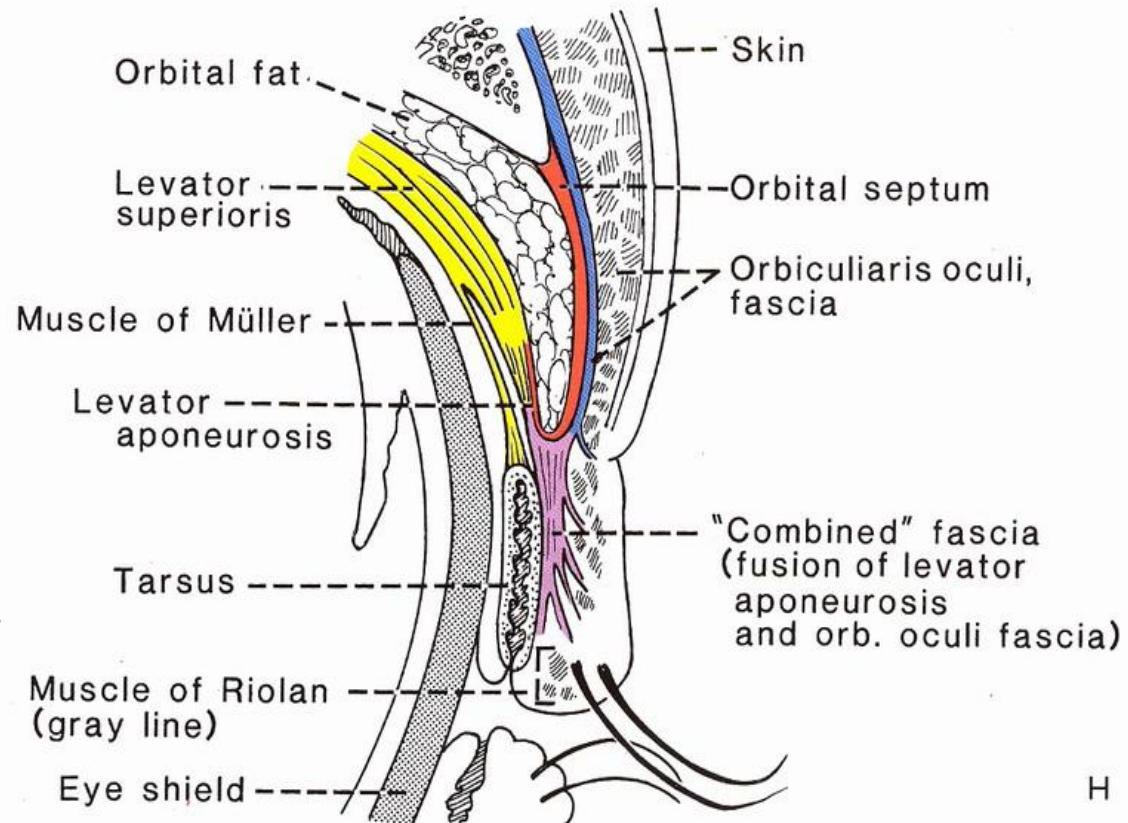


# Management of the eye

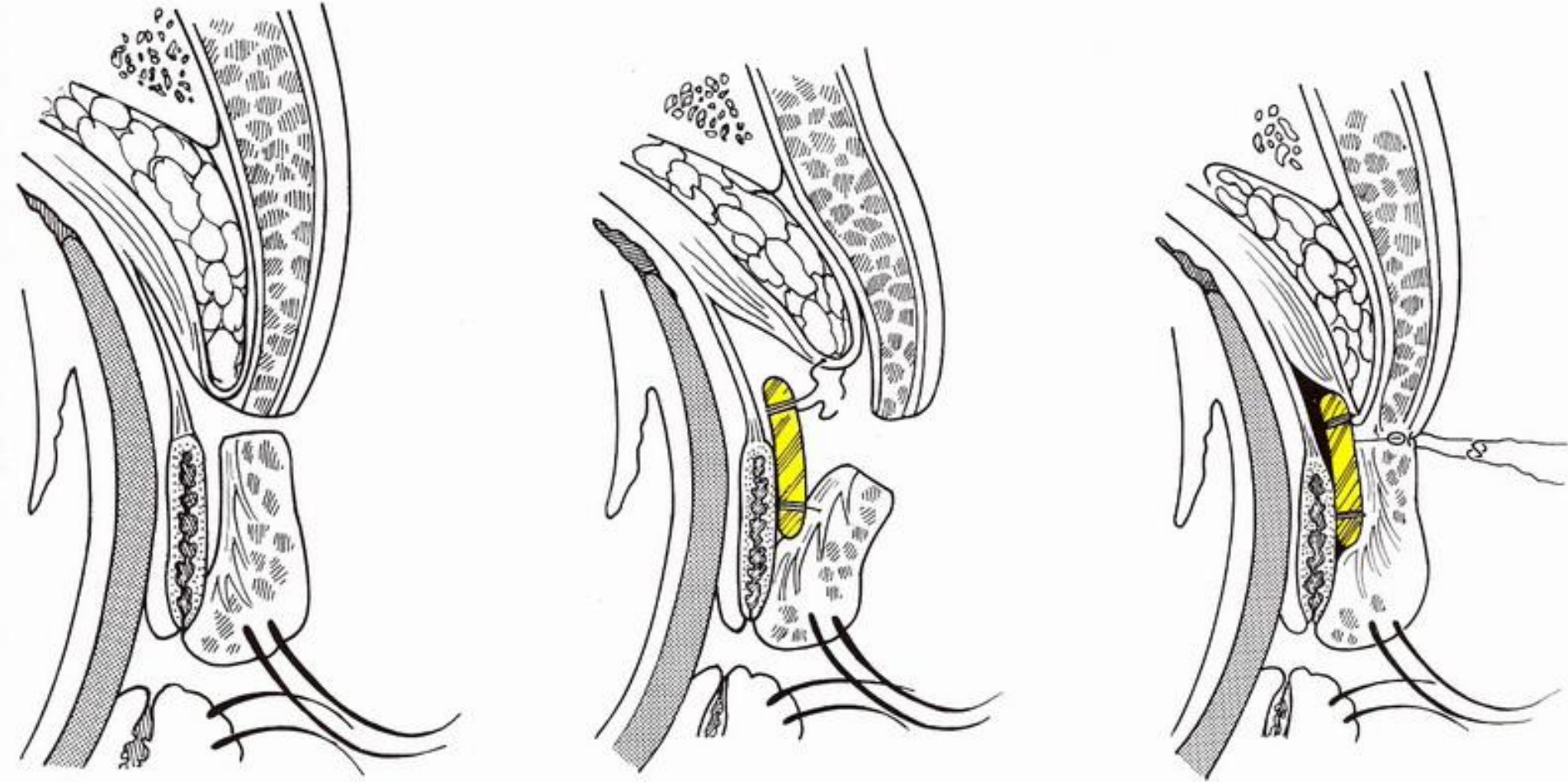
- Upper eyelid : gold implant
- Lower eyelid: lat tarsorrhaphy
- Brow:
  - Suspension with sutures
  - Skin resection

# TECHNIQUE

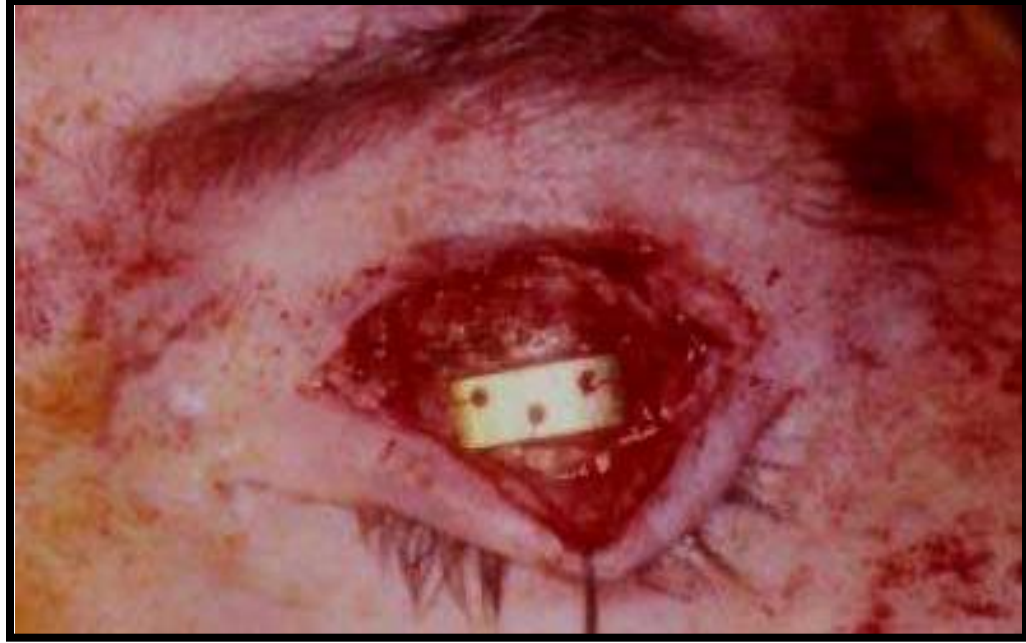
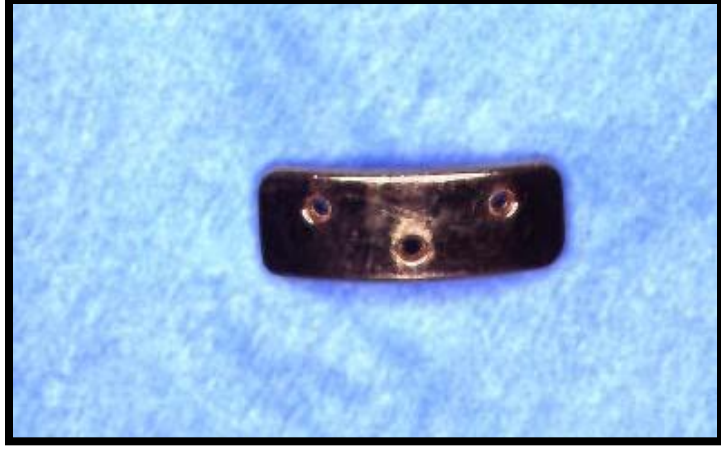- Incision through the sup eyelid fold
- Incision of the orbicularis muscle
- Superior fixation to the septum
- Fixation to the tarsus
- Position middle 1/3 – internal 1/3



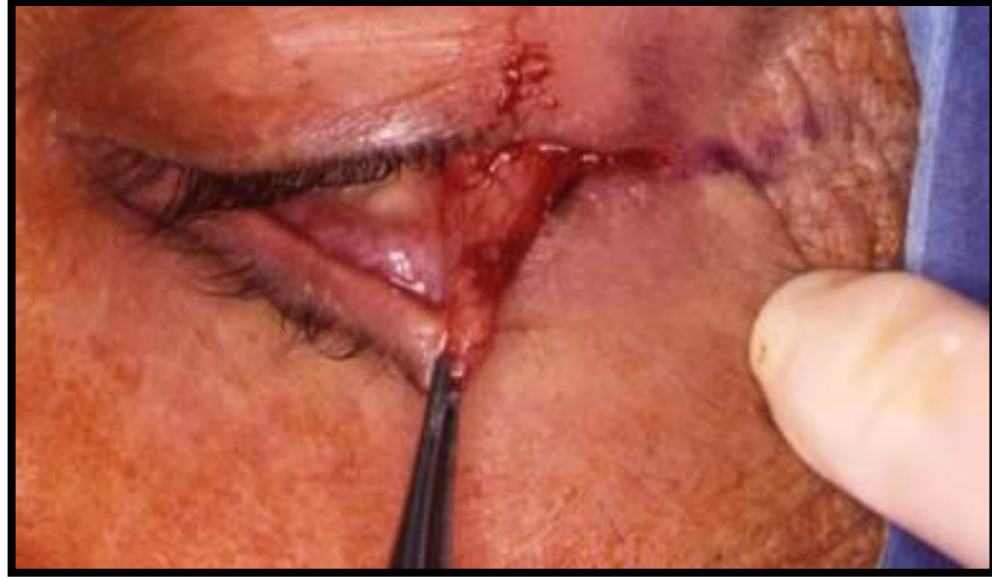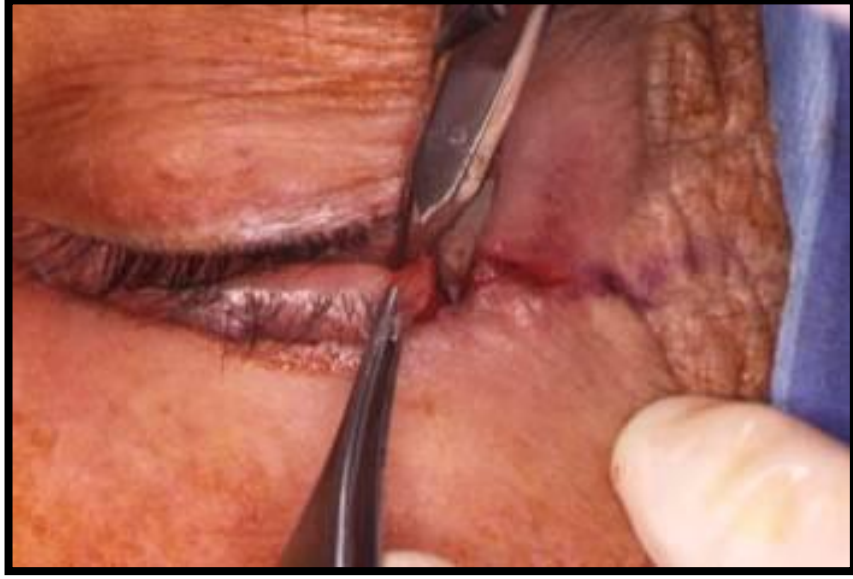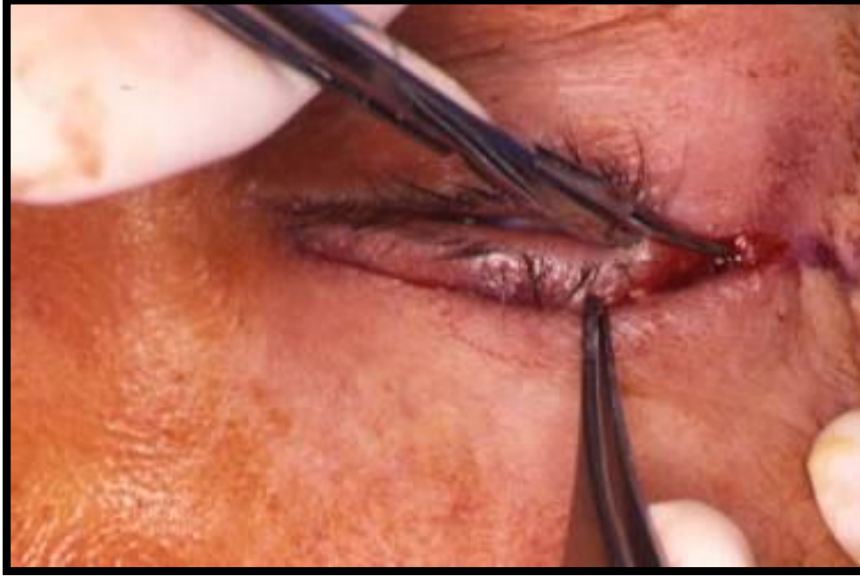# IMPLANT



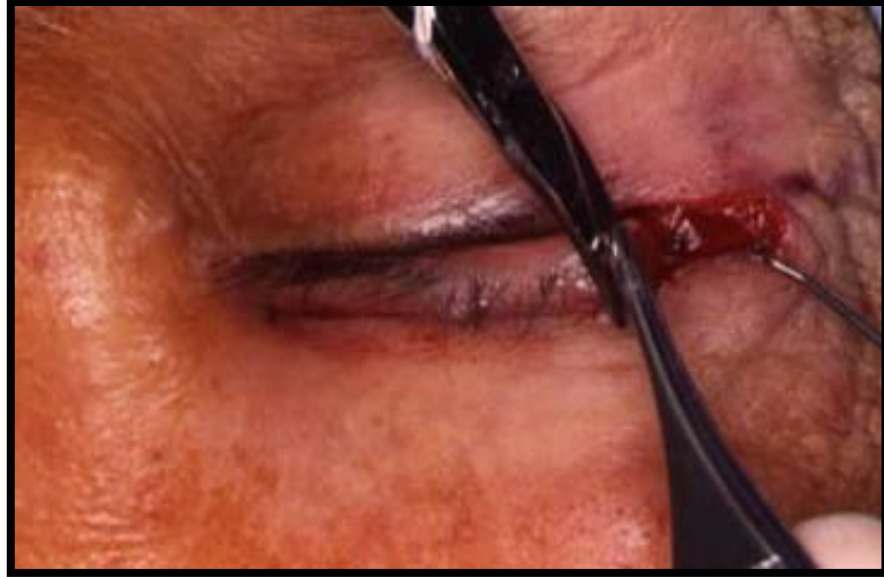
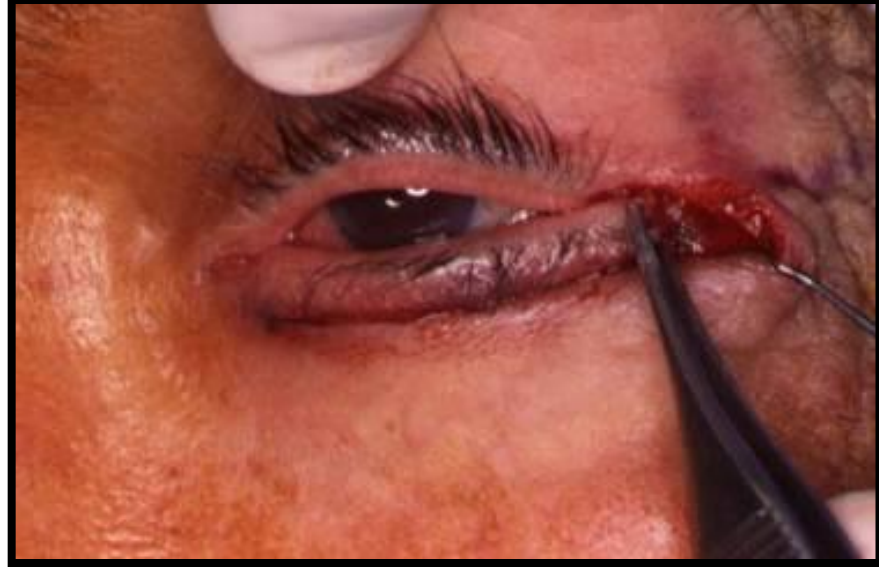
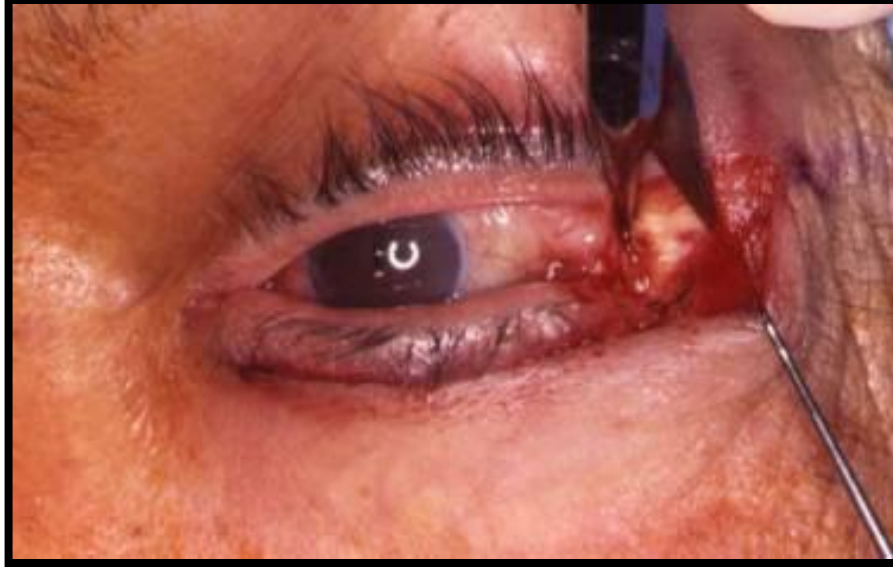

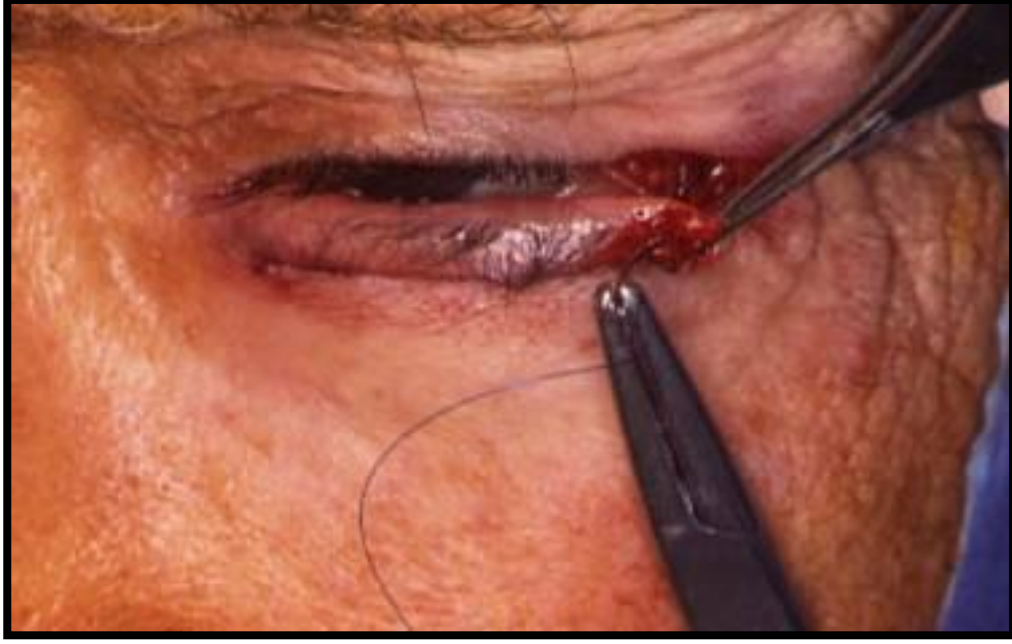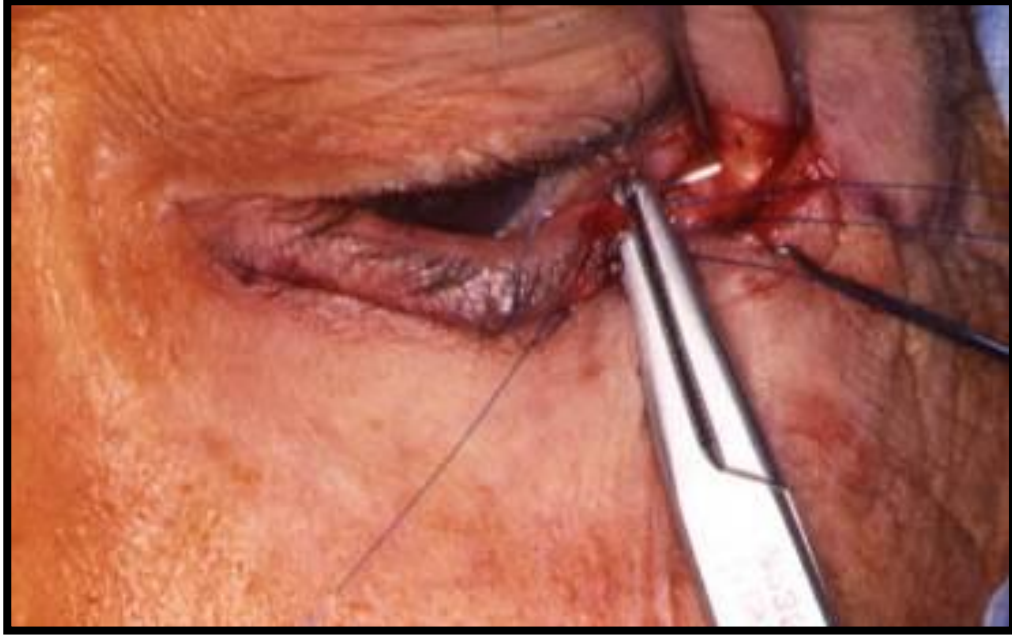# LATERAL CANTHOPEXY









# Take home message : facial reconstruction post parotidectomy

- Nerve grafting + static suspension
- Muscles transfer
  - Temporal myoplasty
  - Free muscle transfert + static suspension
- Static suspension



# Take home message : nerve grafting

- First choice:
  - VII – VII + V-VII + static suspension
- Second choice
  - VII-VII + XII –VII + static suspension
- TT adapted to the clinical situation
- Better results in young patients
- Grafting synchronous with the resection

# Take home message : muscle transfer

- First choice:
  - Temporal myoplasty or with extension Fascia Lata
    - Immediate effect
    - Limited commissural excursion
    - Sometimes unpredictable
    - V intact

# Take home message : muscle transfert

- Second choice:
  - Gracilis transfert
    - Innervation with VII or V
    - Combined with CFNG if V
    - +Static suspension
    - Add volume and contour
    - 2 teams approch
    - Receipient vessels available
    - Better commissural excursion
    - Mouvements after 4-6 months
    - More predictable with V



## Take home message : static suspension

- Nowadays should not be considered as an unique option
- Adjunctive procedure
- Combined with nerve grafts or free muscle transfert
- Technical considerations